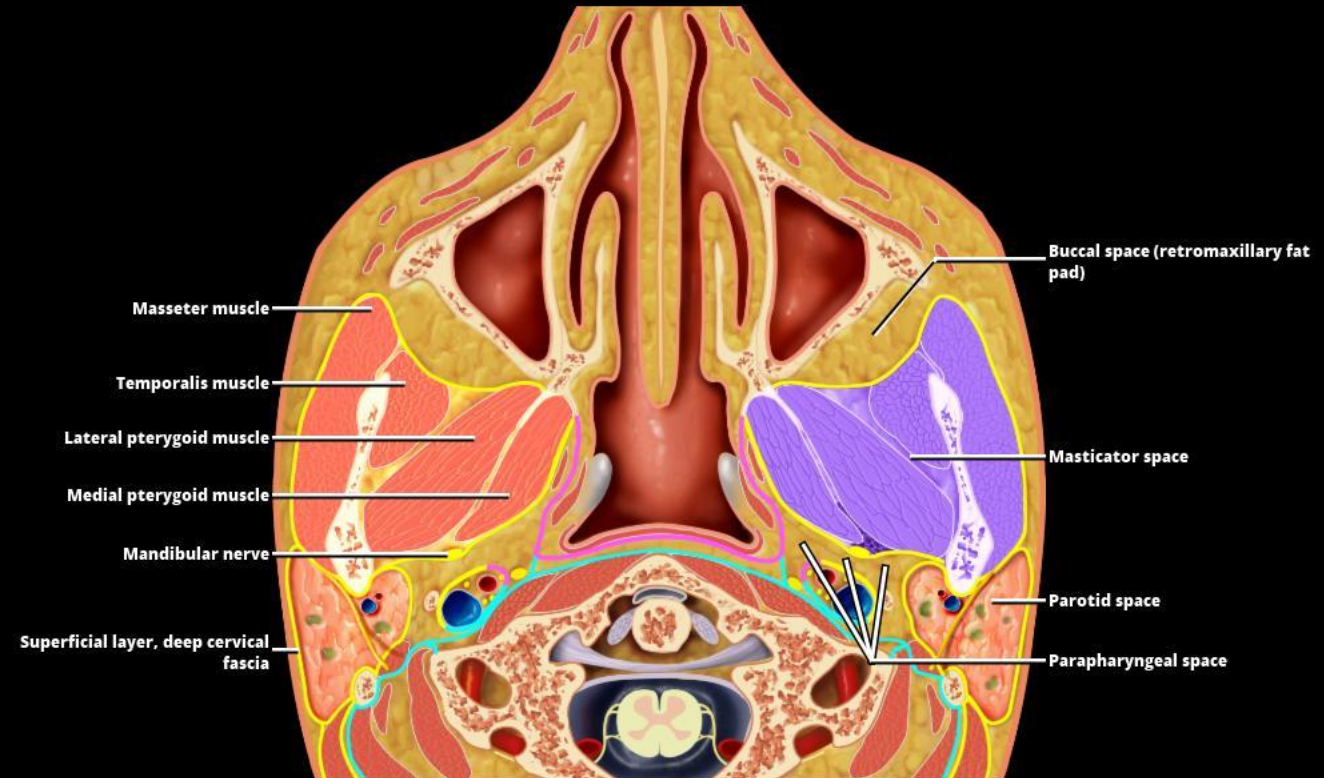


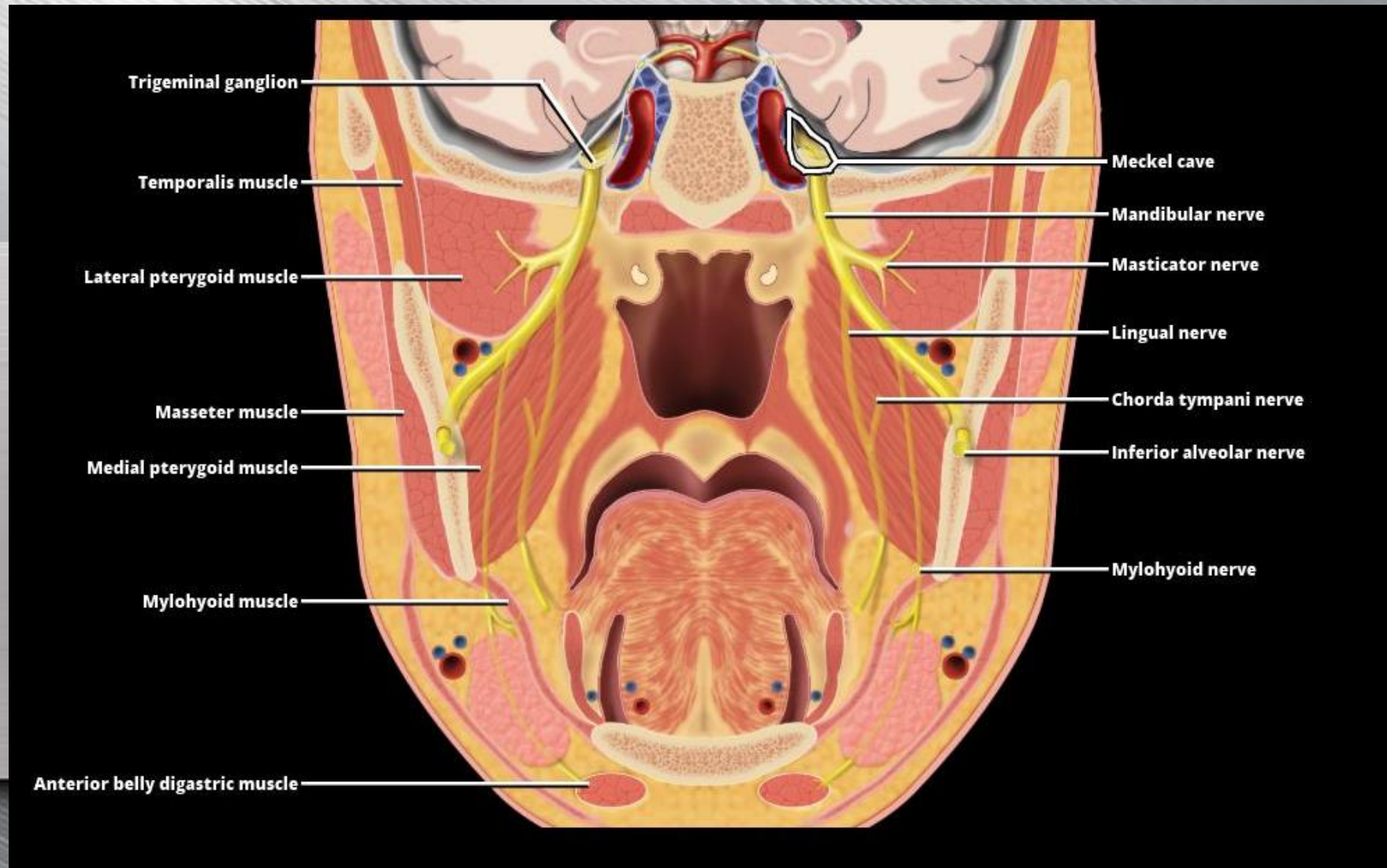
Masticator space enclosed by the superficial layer of deep cervical fascia (yellow line).

- Muscles of mastication
 - Medial and Lateral pterygoid
 - Temporalis
 - Masseter muscles

Mandibular nerve (CNV3 main trunk) lies just posterior to medial pterygoid muscle inside the superficial layer of deep cervical fascia.

Buccal space is anterior, while the parapharyngeal and parotid space are posterior to the masticator space.





Mandibular division of the trigeminal nerve. Note CNV3 exits skull base without entering the cavernous sinus.

Perineural route up the **mandibular nerve (V3)** through the foramen ovale into the intracranial compartment.

Both primary masticator space malignancy and squamous cell carcinoma of the oral cavity can access the intracranial compartment in this manner.

