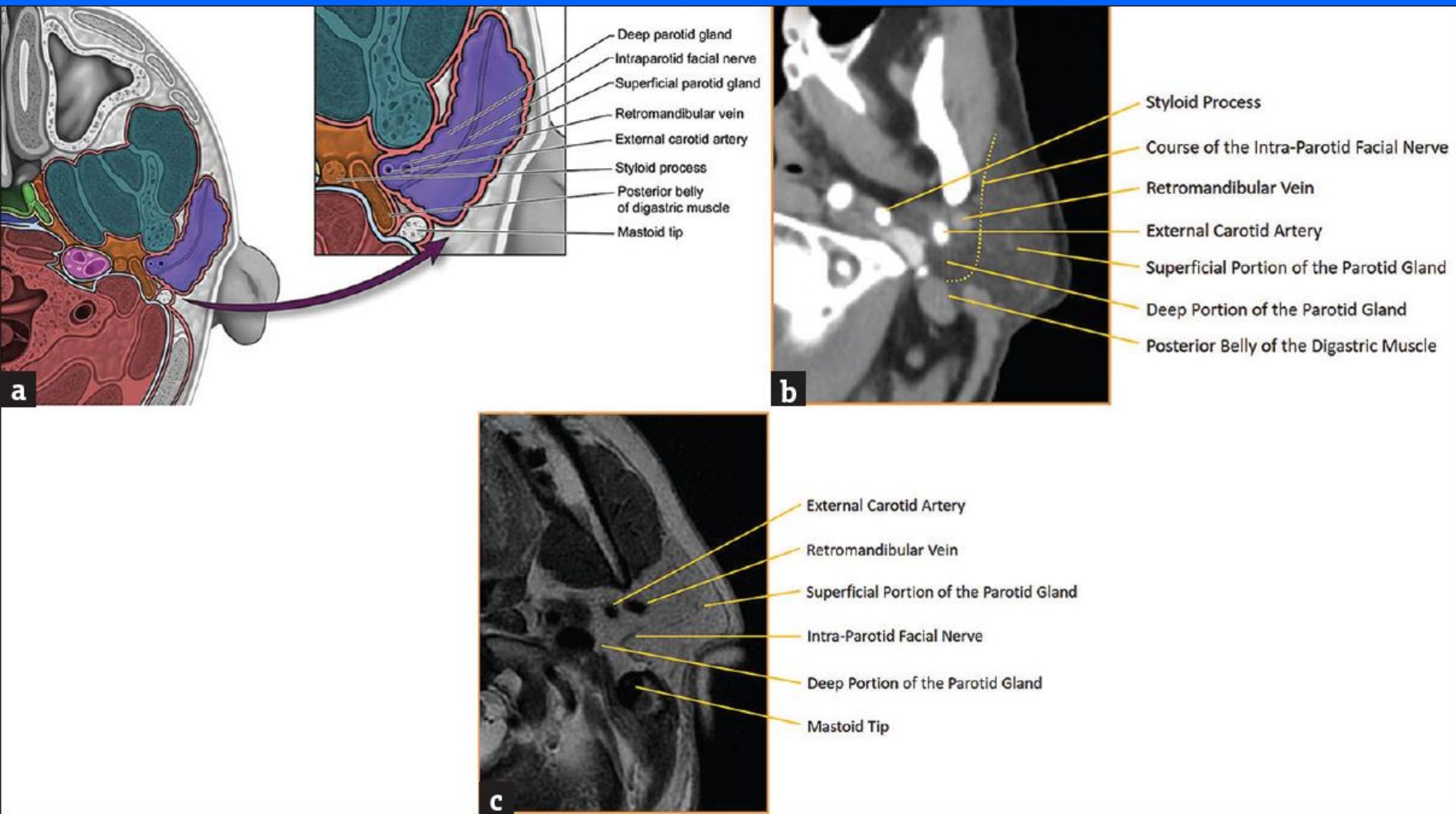
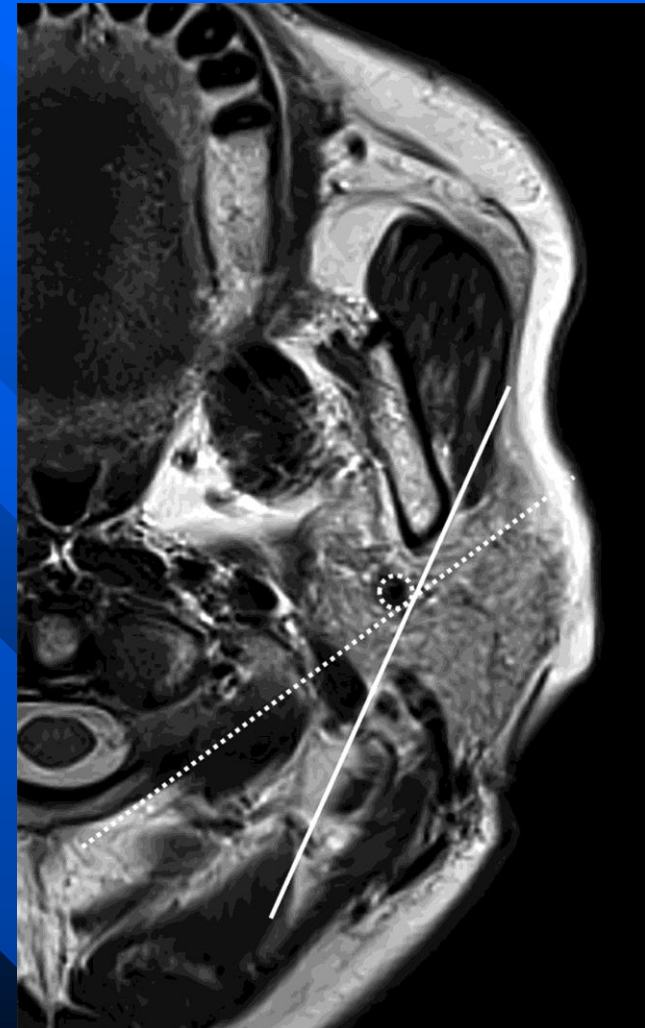
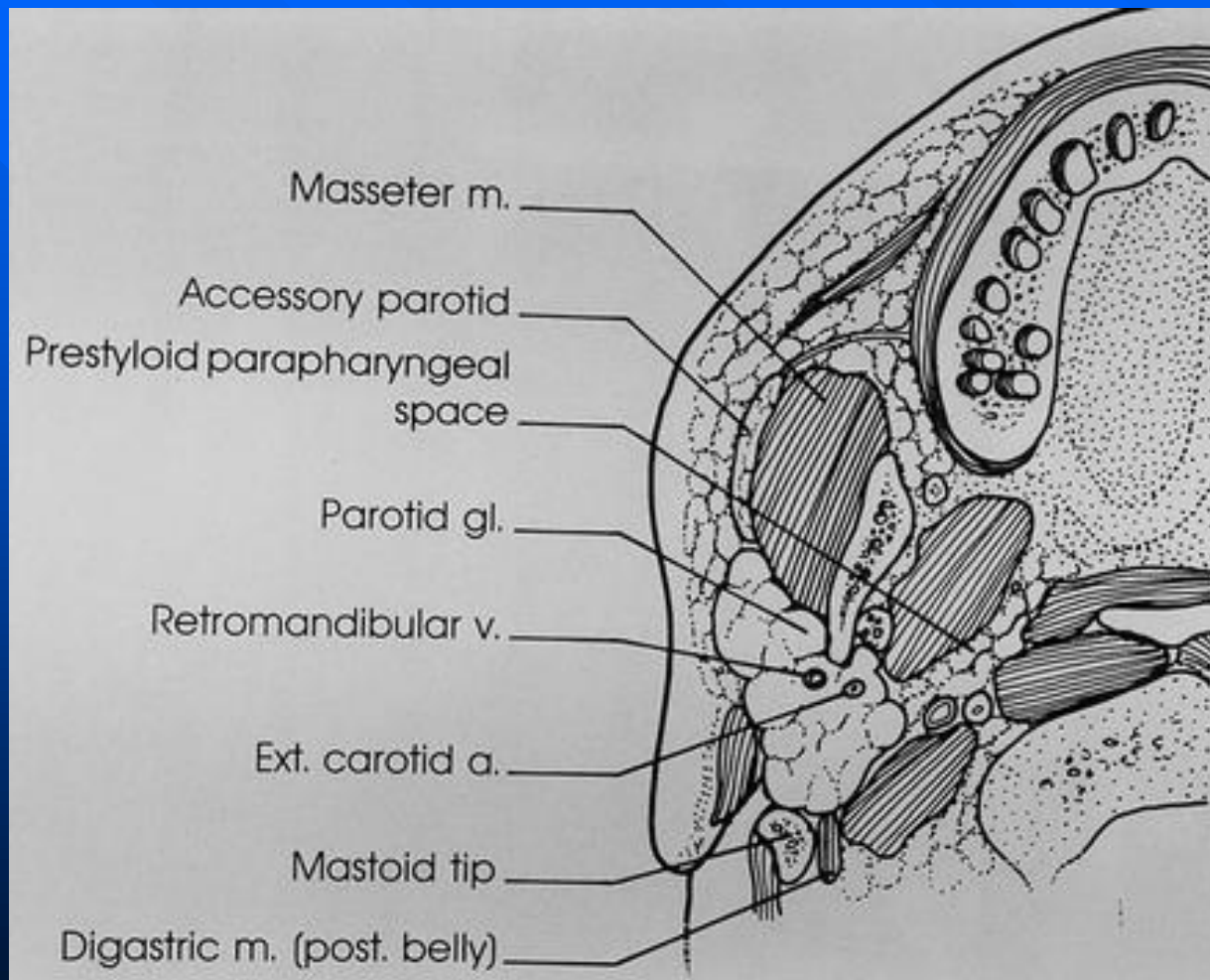
Although not a true fascial plane, the **intraparotid facial nerve** separates the superficial and deep portions, an important distinction to make when describing a lesion's location before excision.

Indirect methods to approximate the intraparotid facial nerve: facial nerve line (solid line), retromandibular vein (dotted circle), and Utrecht line (dotted line).

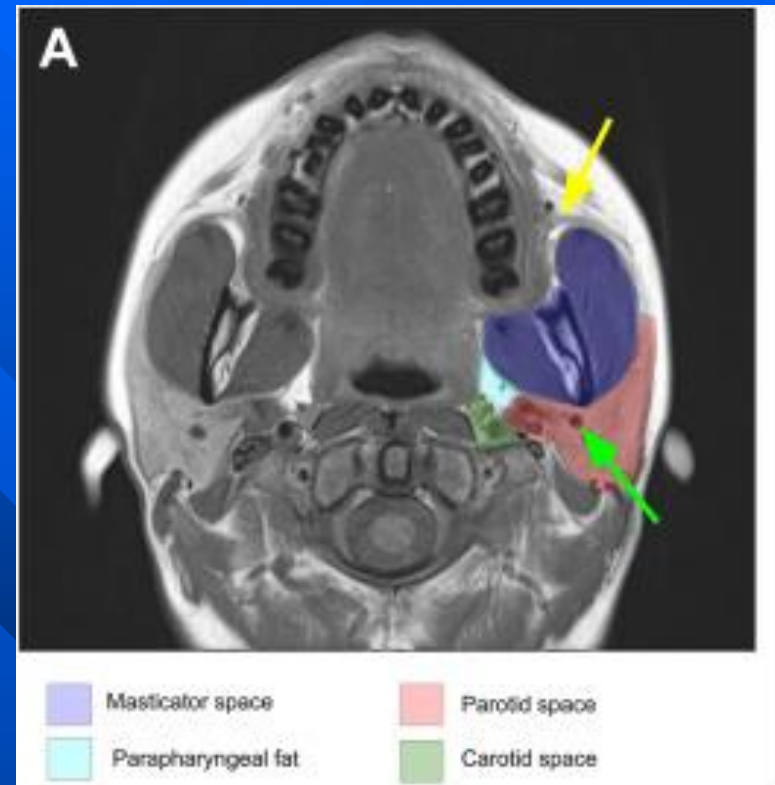
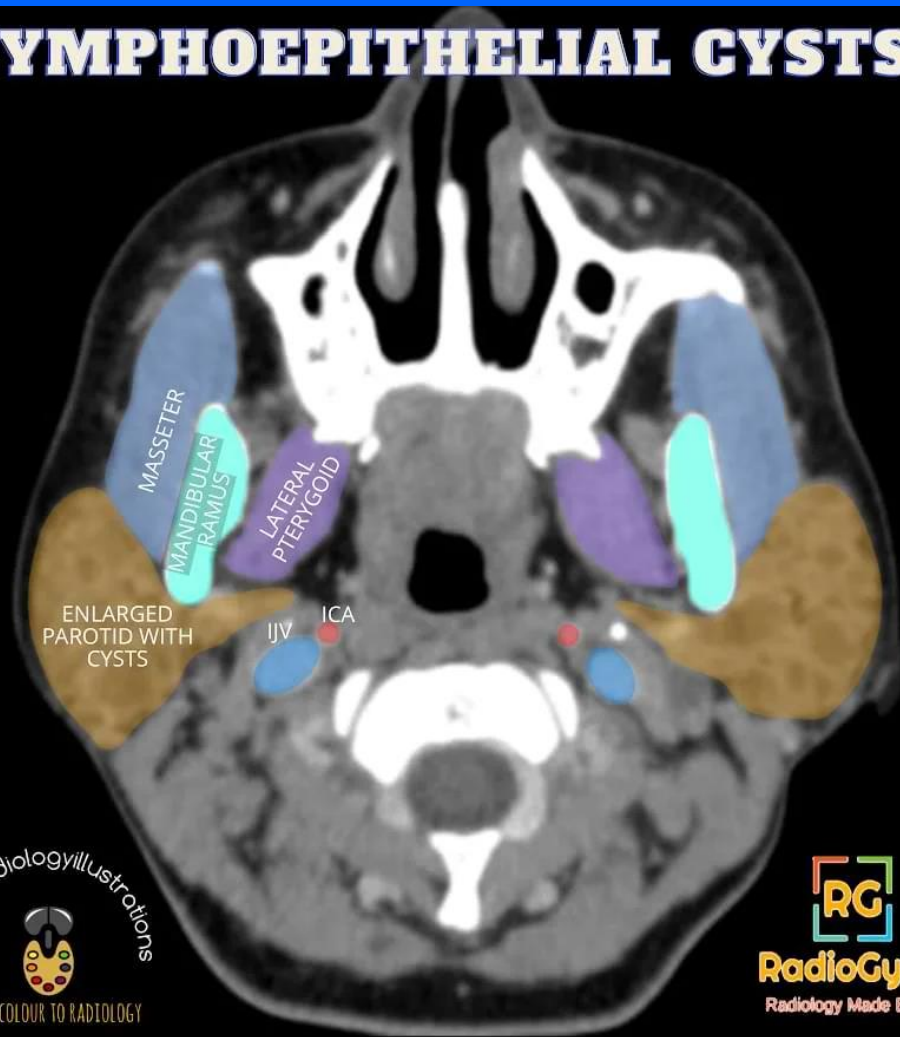
- Facial nerve line (FNL)
 - Connects the lateral surface of the posterior belly of the digastric muscle to the lateral surface of the ascending ramus of the mandible.
- Utrecht line (UL)
 - Connects the most dorsal point observed on the ipsilateral half of a vertebra to the most dorsal point of the retromandibular vein (RMV)

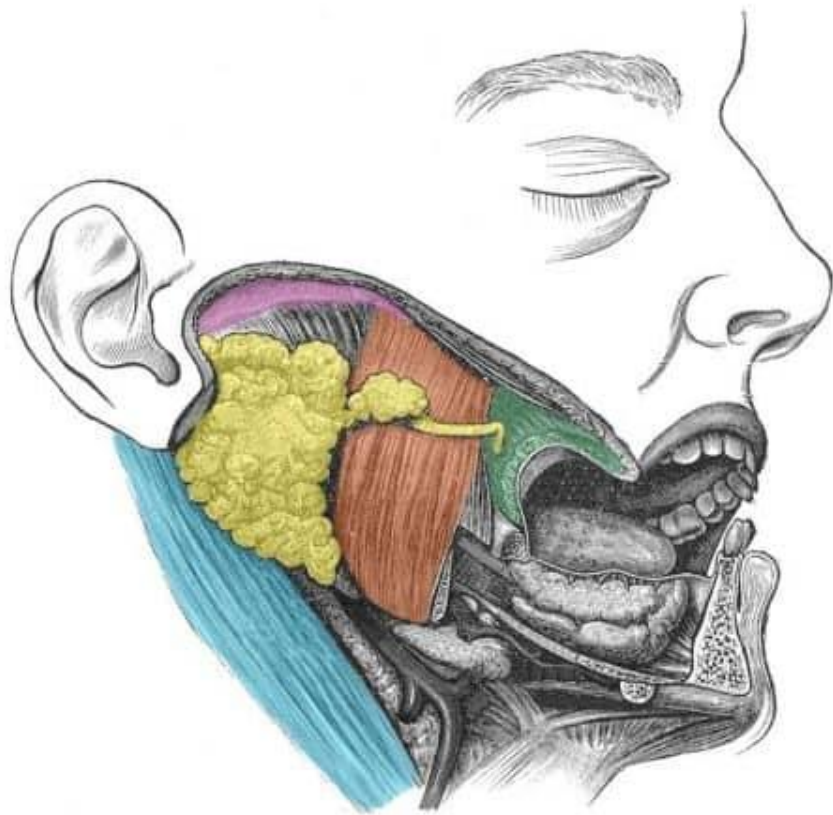


Parotid Gland Anatomy



LYMPHOEPITHELIAL CYSTS





-  **Parotid gland and duct**
-  **Zygomatic arch** (superior border)
-  **Sternocleidomastoid** (posterior border)
-  **Masseter** (anterior border)
-  **Buccinator**