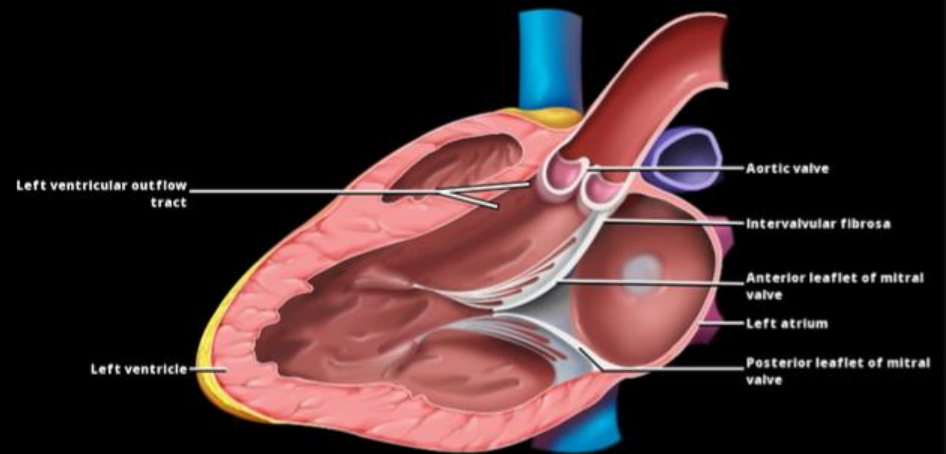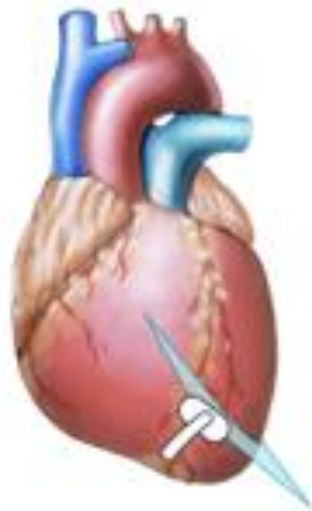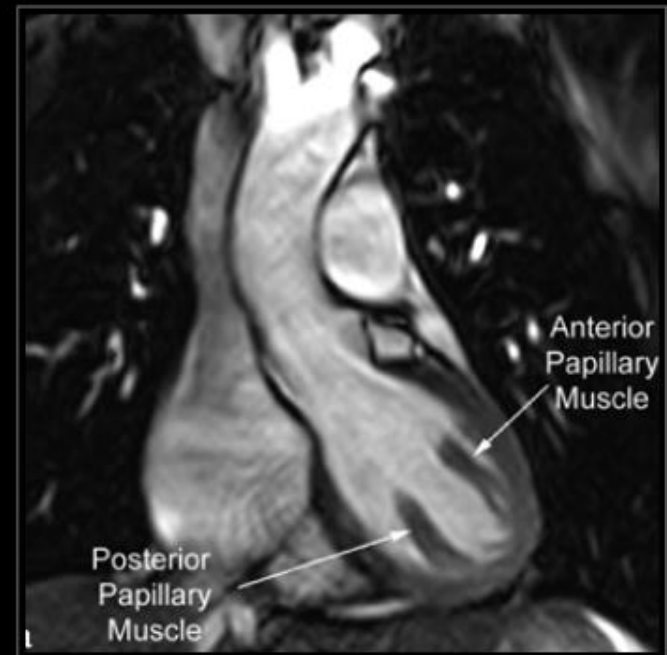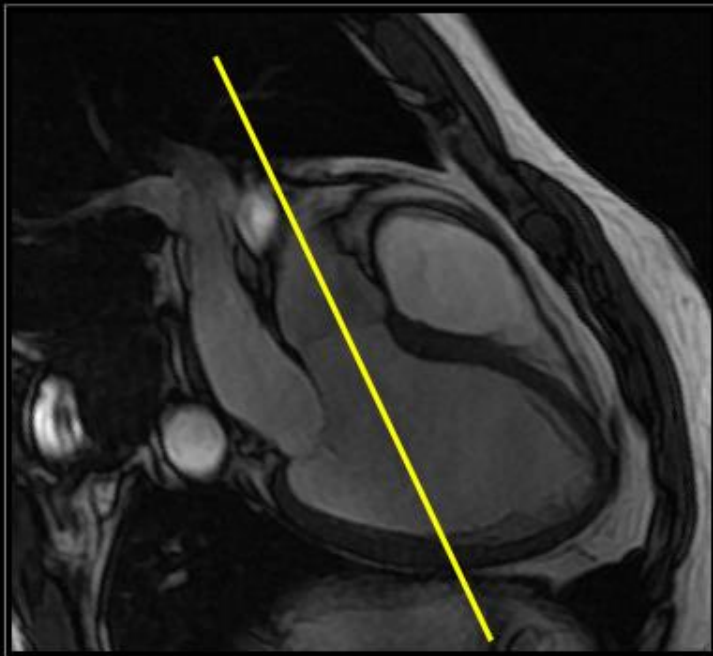


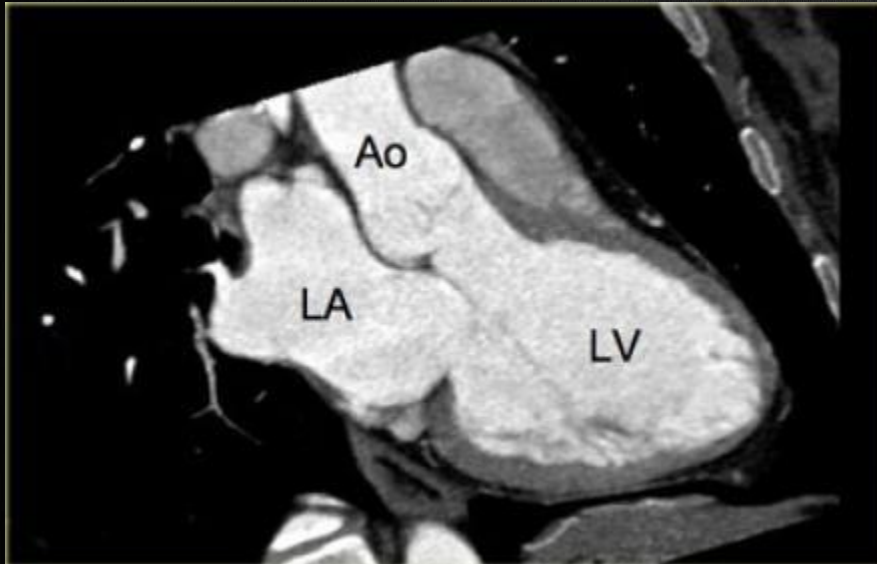## Left Aortic Outflow Tract (LVOT) View



**Bisect ascending aorta and aortic valve on 3-chamber view**

# 3-chamber view



- When the border between the mitral and aortic valves is localized on the axial slices and the images are rotated from this point.
- A 3-chamber view like the image on the left can be reconstructed.
- On this image, the left atrium, left ventricle, mitral-, aortic valve and proximal aorta are visible.