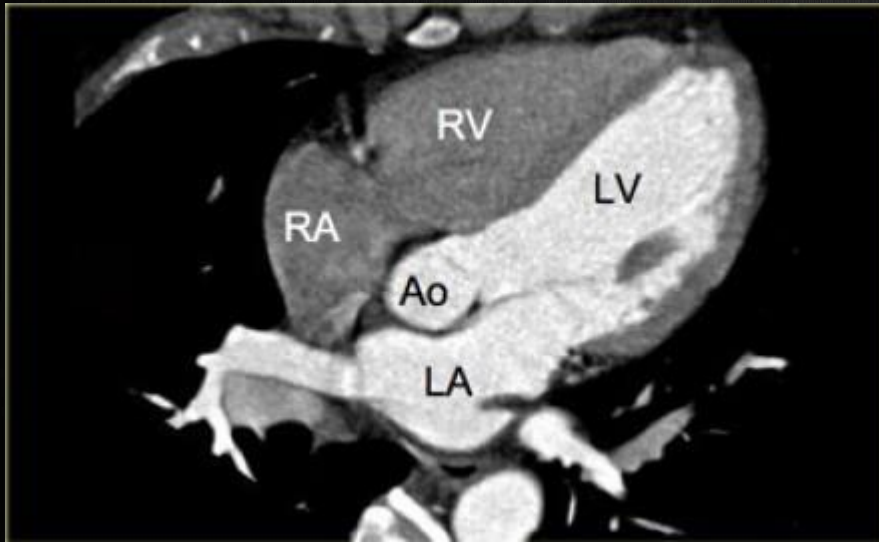


5-chamber view



- Similar to the 4-chamber view, but additionally displays the aortic valve and left ventricular outflow tract.
- This view is achieved by rotating the 4-chamber view a little more cranially.