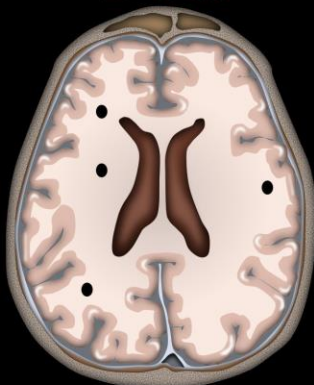


Calcification

- I HeaR = Infection & Hematoma give a Rock pattern
- I GYRate = Infarct give a GYRiform
- And finally...
- I Dab = Infection gives tiny Dabs or Dots everywhere
- For the rest:
- If they are grouped: think tumor or vascular
- If they are diffusion: think metabolic
- If they are along the ventricle: think TORCH

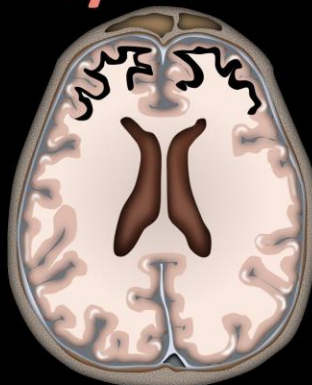
INTRACRANIAL CALCIFICATIONS BRAIN STONES

Dots



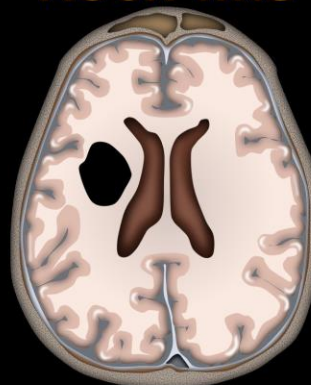
Post-infectious

Gyriform



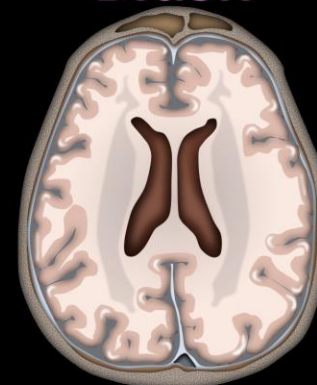
Congenital or post-infarct

Rock-like



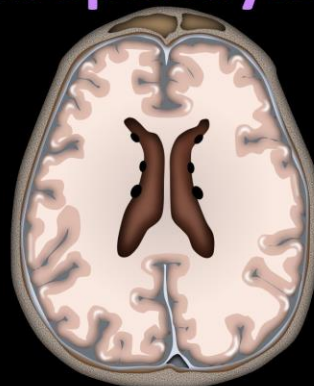
Prior infection or
hematoma

Blush



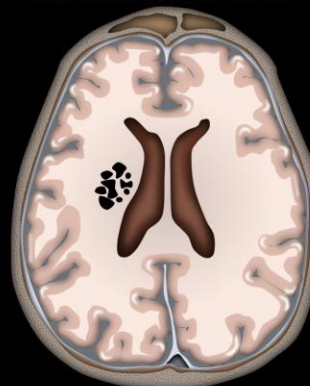
Metabolic

Subependymal



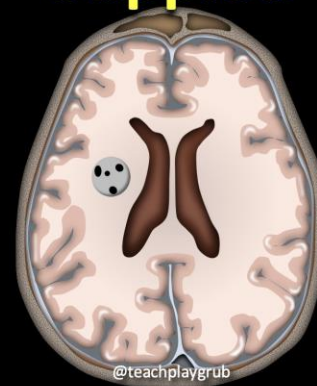
Congenital/
TORCH

Clustered



Tumor, post-treatment,
post-trauma, vascular

Stippled



Tumor/vascular
malformation