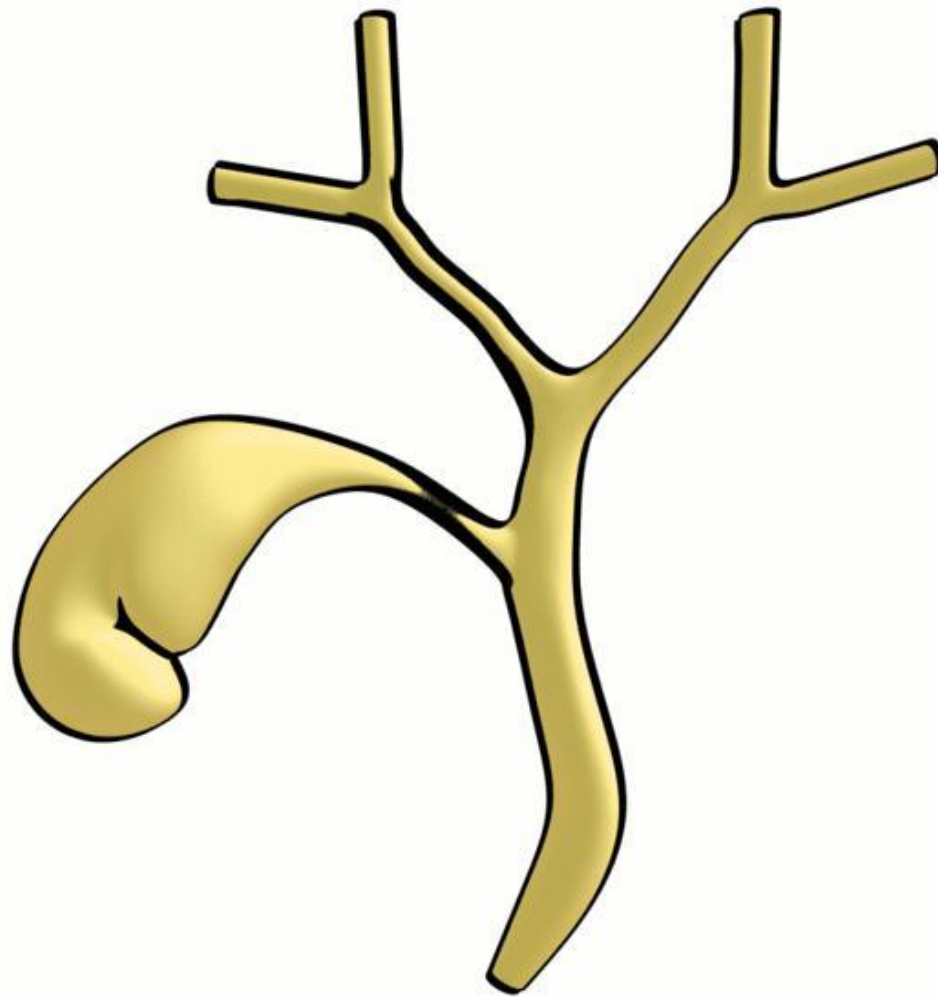


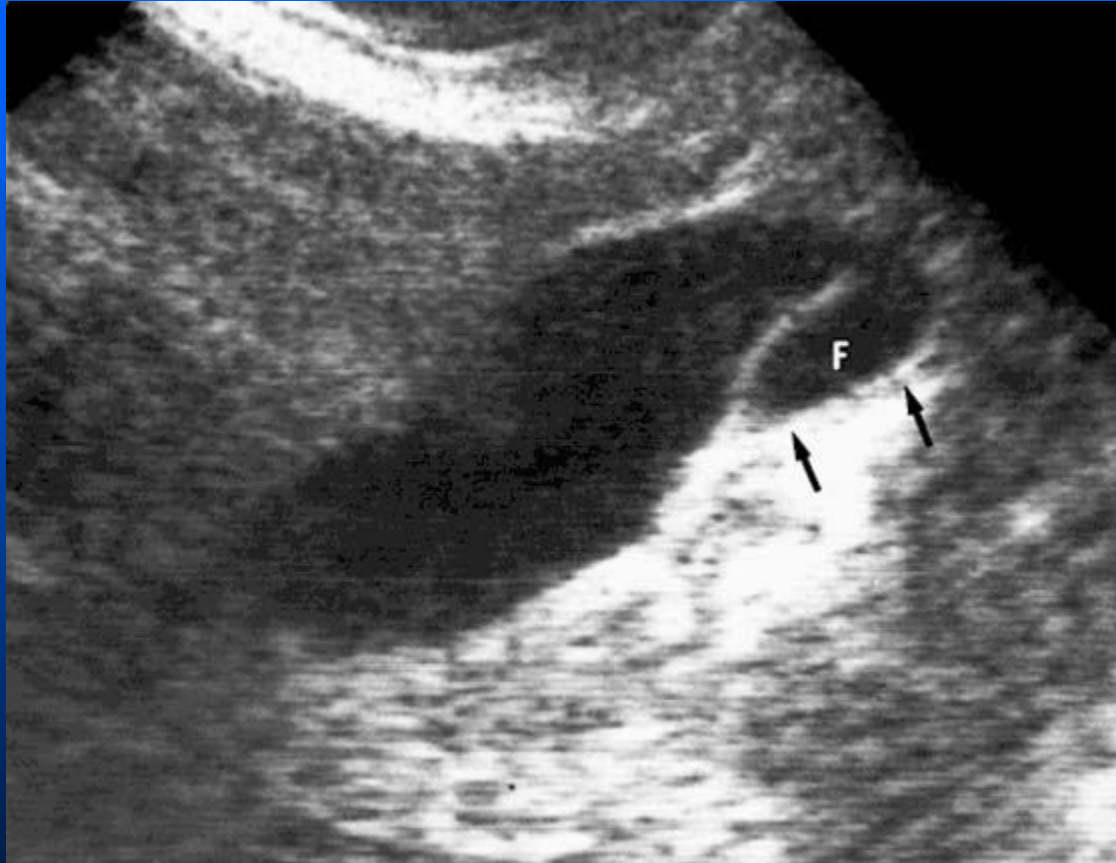Phrygian cap

- Most common congenital anatomic variant of the gallbladder.
- It denotes folding of the fundus back upon the gallbladder body and is asymptomatic with no pathological significance.



Phrygian cap

Phrygian cap



Longitudinal views show a Phrygian cap deformity (arrows) caused by folding of the fundus (F) over the body of the gallbladder