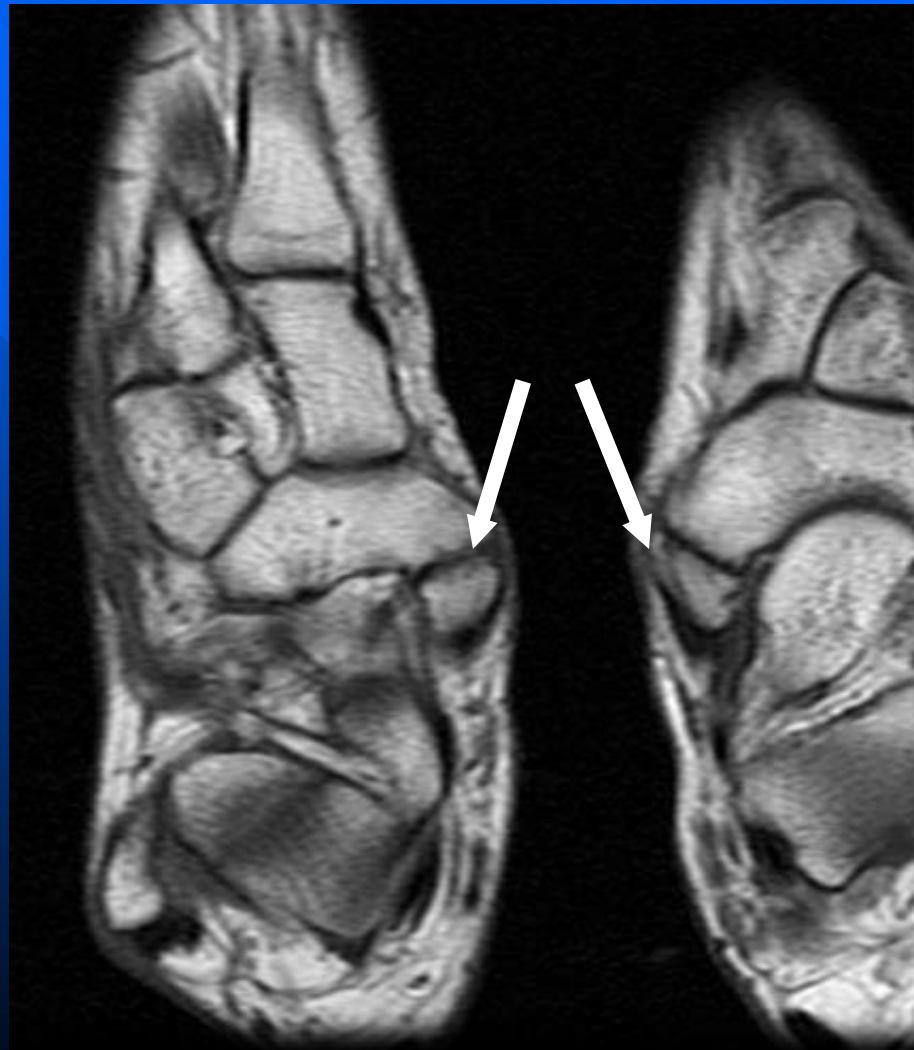


# Bilateral accessory navicular bones (Type II AN)



# Accessory navicular bones

- Type I AN (30%) represents a sesamoid bone in the posterior tibialis tendon at the insertion into the navicular. They tend to be round or oval and may be seen up to 5mm medial and posterior to the medial aspect of the navicular.
- Type II AN (70%) represents an accessory ossification in the tubercle of the navicular. These are often triangular or heart shaped, usually within 1-2 mm of the medial and posterior aspect of the navicular bone. These are usually the ones that are symptomatic with local pain and tenderness