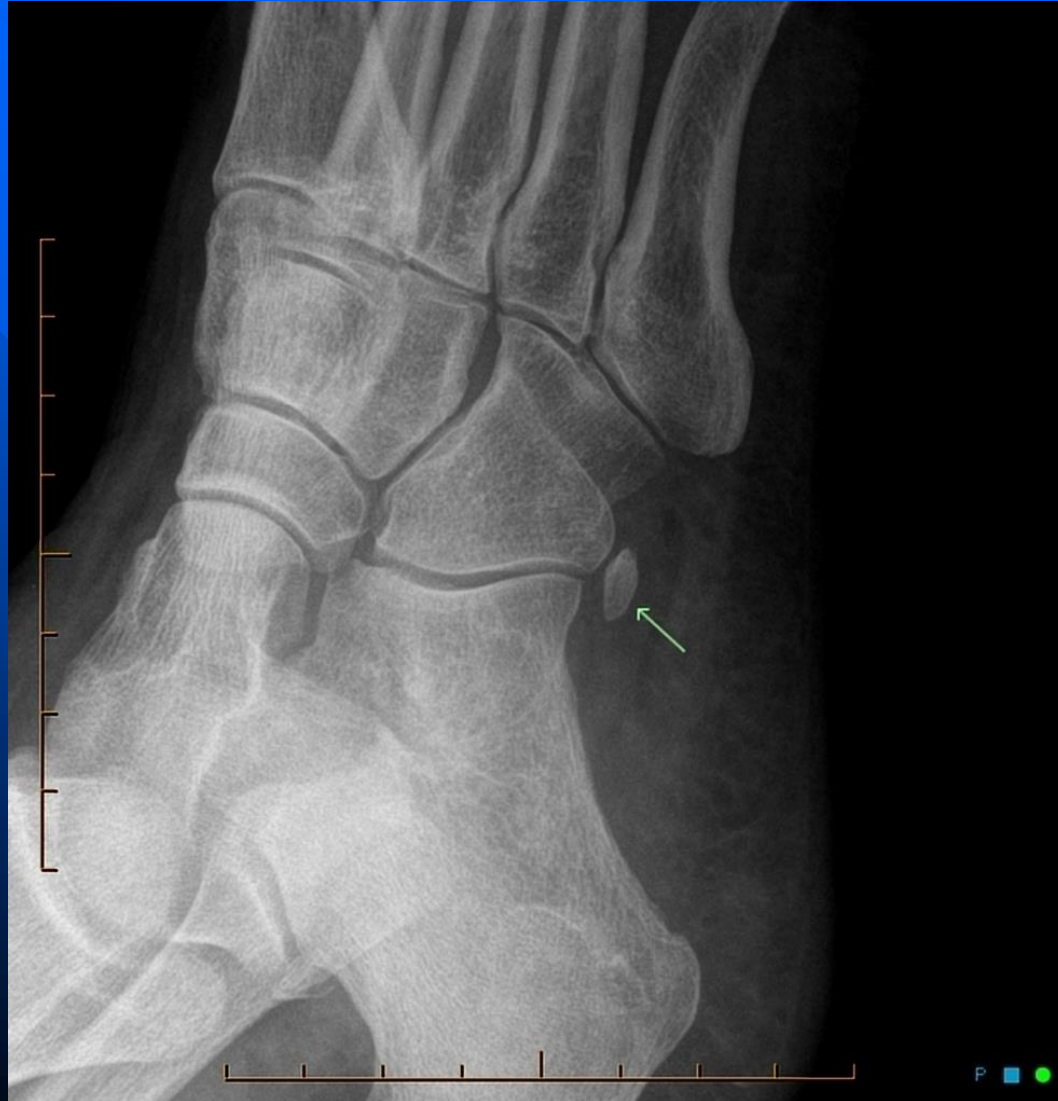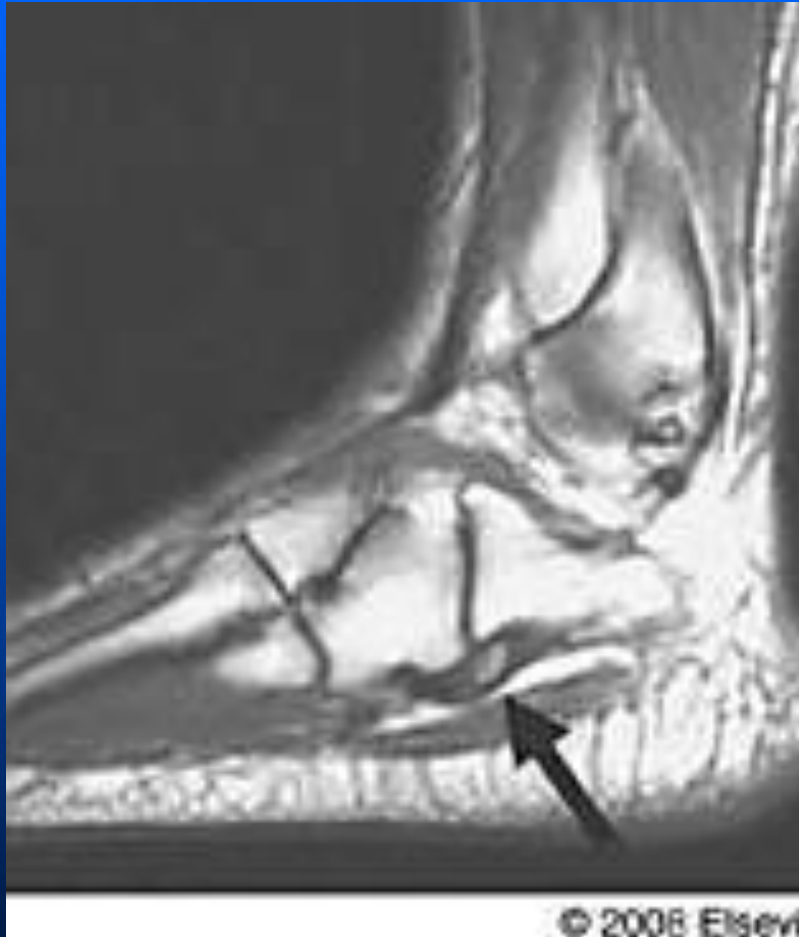


# Os Peroneum



# Painful Os Peroneum Syndrome



- Prominent os peroneum (*arrow*) incorporated into the peroneus longus sheath adjacent to the cuboid.
- Sagittal STIR MR image shows edema within the ossicle

# Painful Os Peroneum Syndrome

