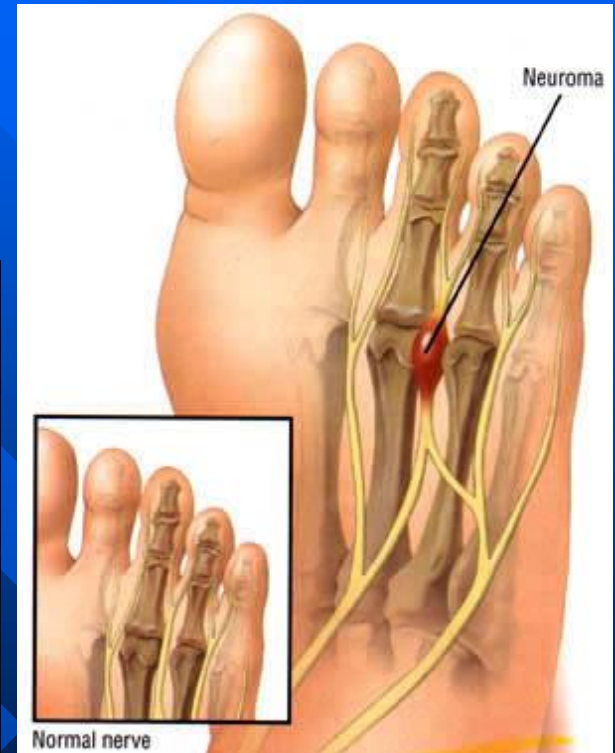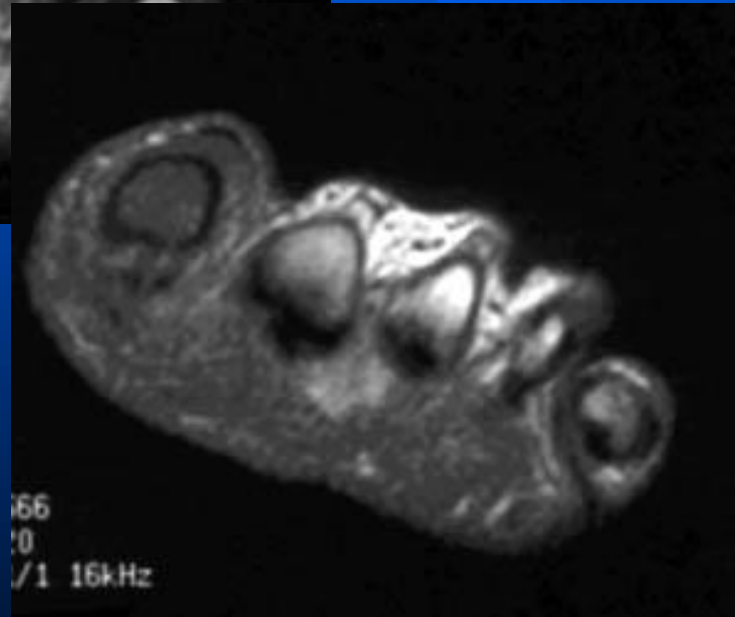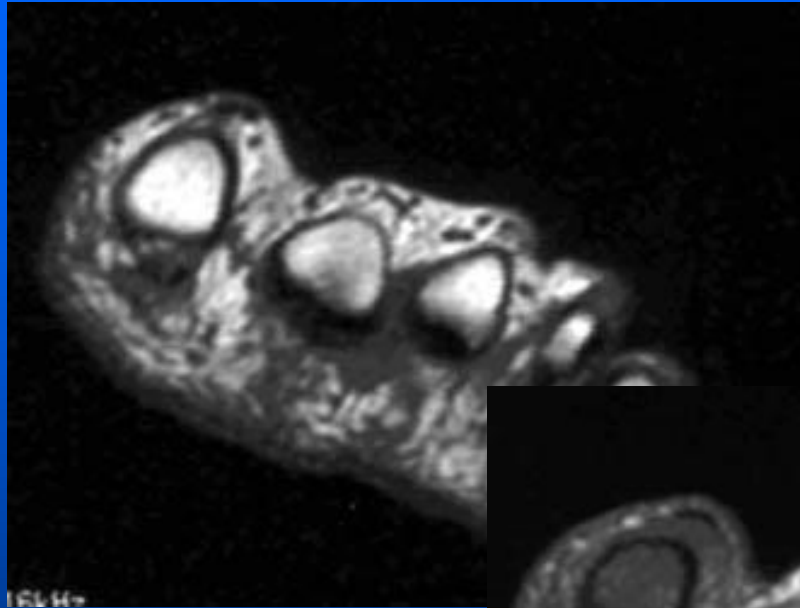


Morton's Neuroma (shwanomas T2 bright)



Post

Morton's Neuroma

- Best diagnostic clue: Soft tissue mass between \pm distal to 3rd + 4th metatarsal heads
- Entrapment neuropathy secondary to compressive forces against deep transverse intermetatarsal ligament
- Fibrotic response: Not true tumor.
- Plantar foot pain
- Women with high heel shoes