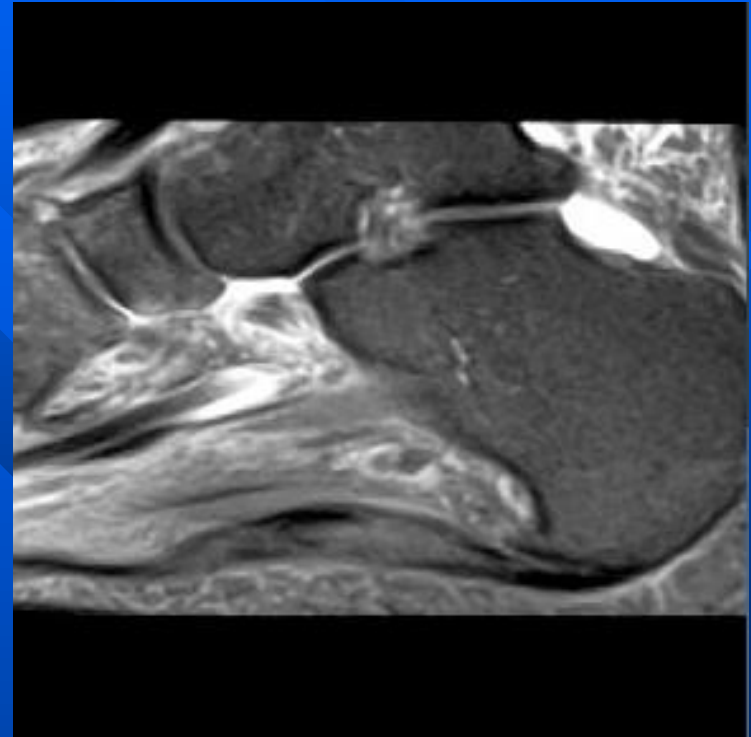
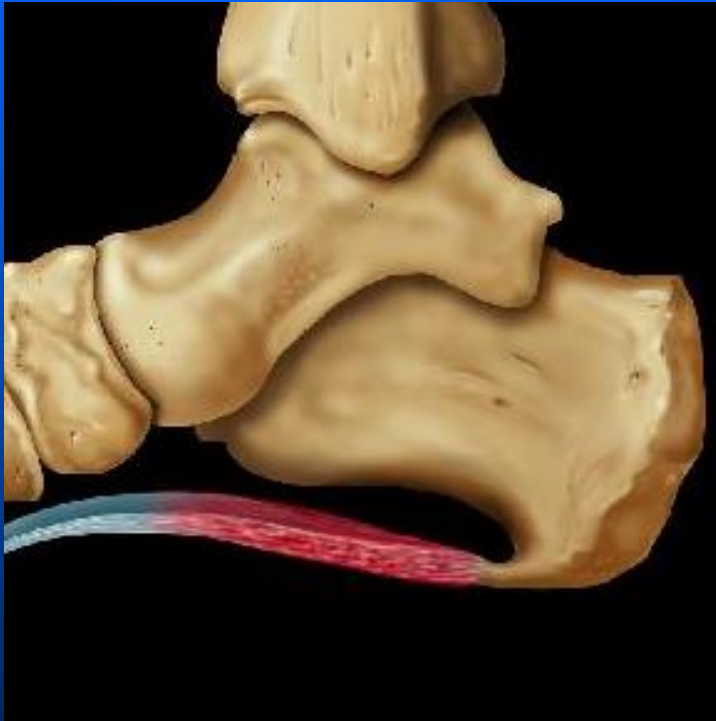


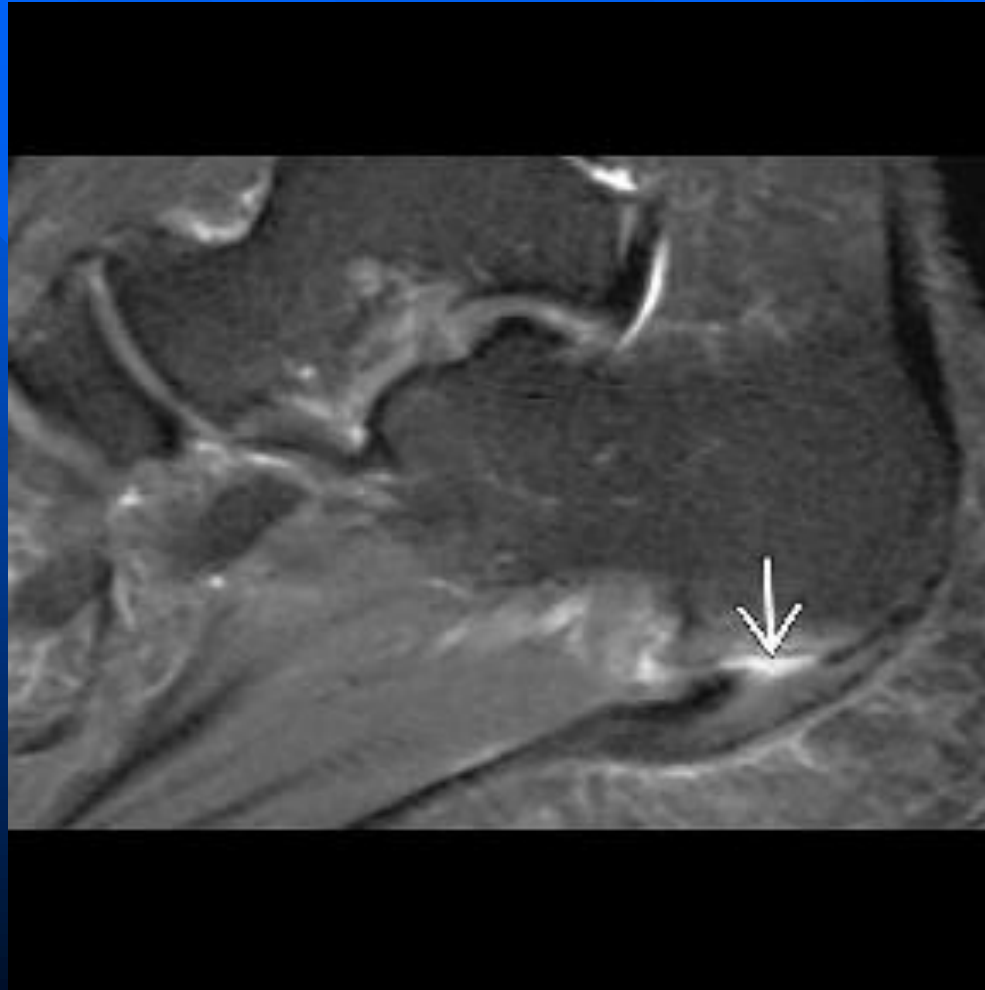
Plantar Fasciitis



Plantar Fasciitis

- **Imaging Findings**
- Best diagnostic clue: Hyperintensity (T2WI) of plantar aponeurosis adjacent to os calcis attachment
- Increased plantar fascia thickness to 7 or 8 mm (**normal thickness 3 or 4 mm**)
- Intermediate to hyperintense thickening proximal plantar fascia on T2WI
- Athletes and obese middle age females

Plantar Fasciitis



Plantar faciitis

