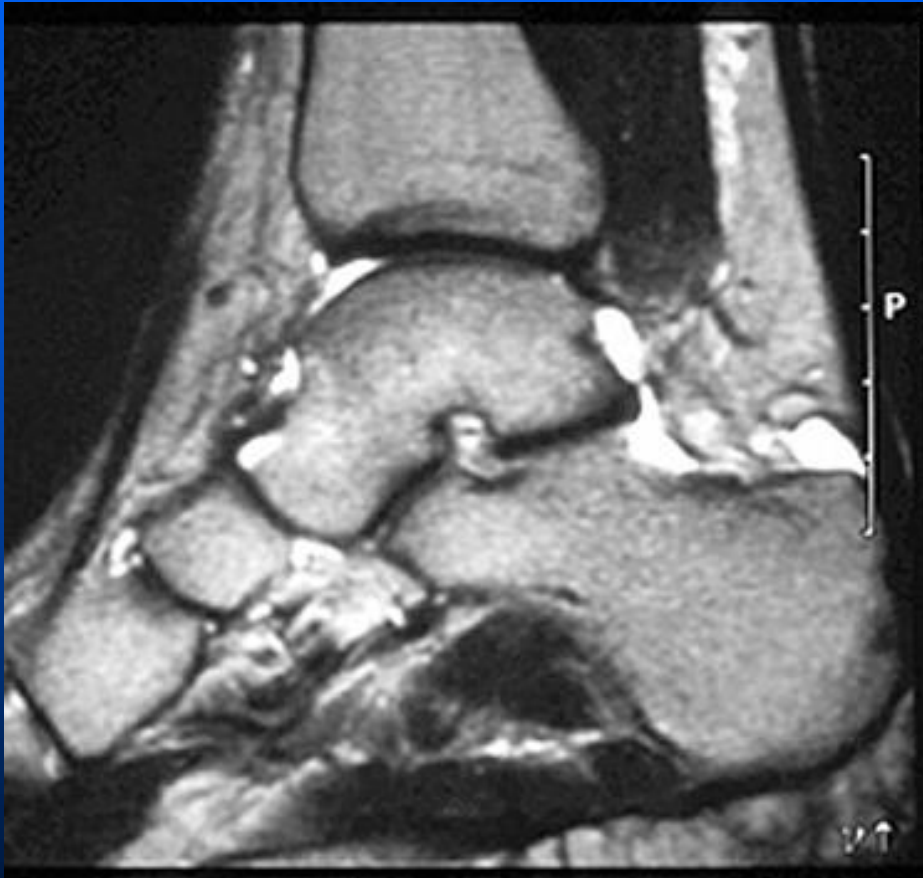


Retrocalcalcaneal bursitis



This is a synovial lined bursa which can become symptomatic in athletes, especially those who wear high top shoes. It is also a frequent target site for inflammatory arthritis such as rheumatoid, psoriatic and Reiters arthropathies

Retrocalcaneal bursal erosion can be seen in RA, psoriasis and Reiter's

