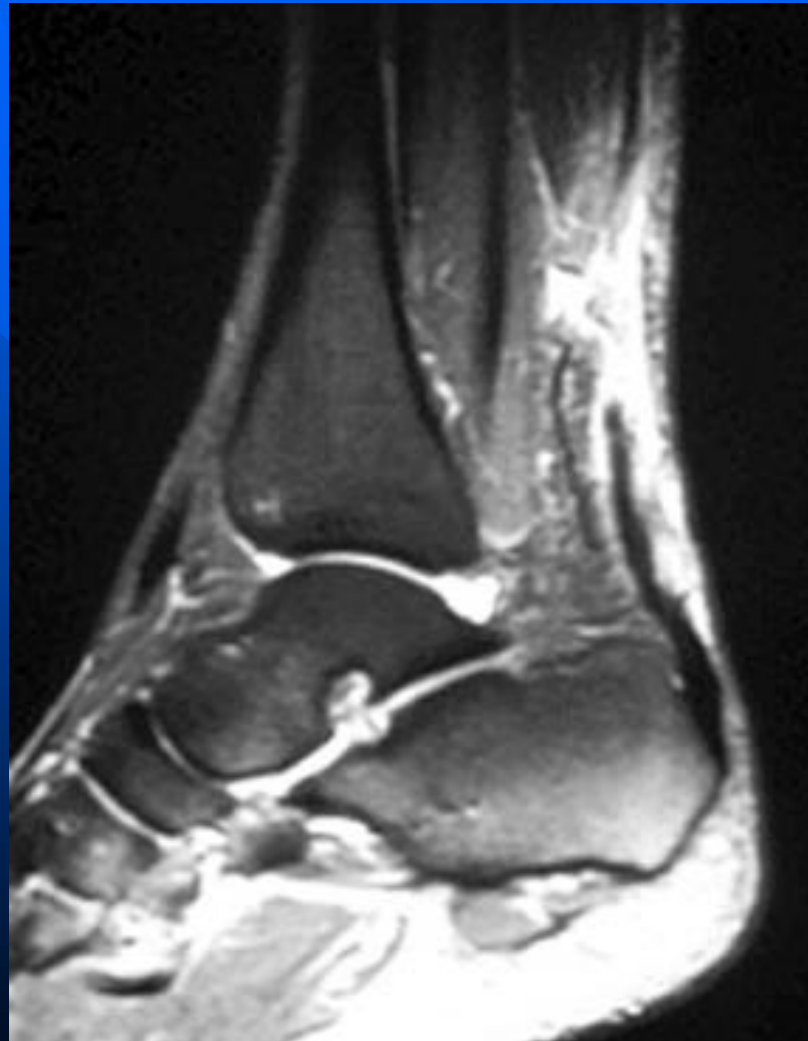
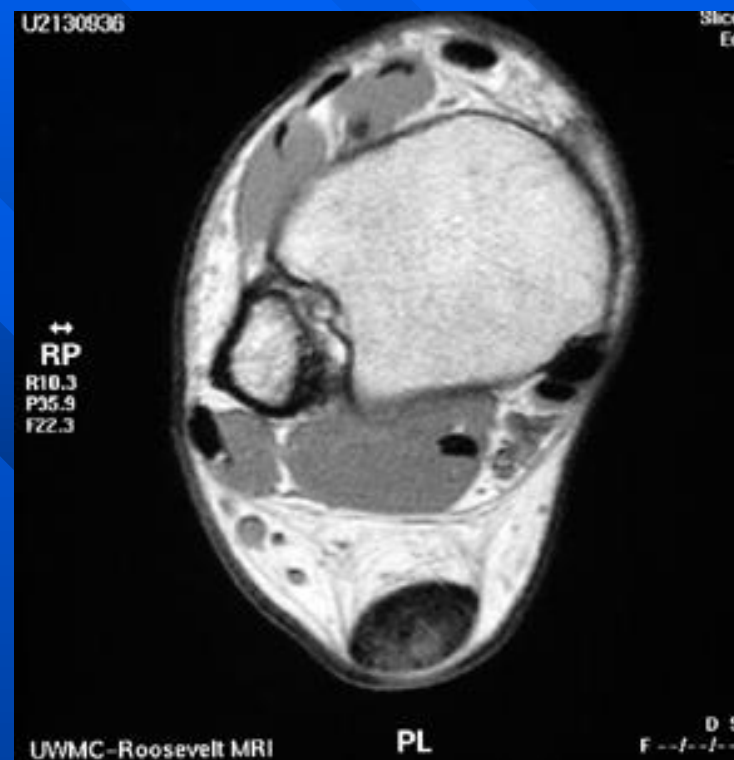
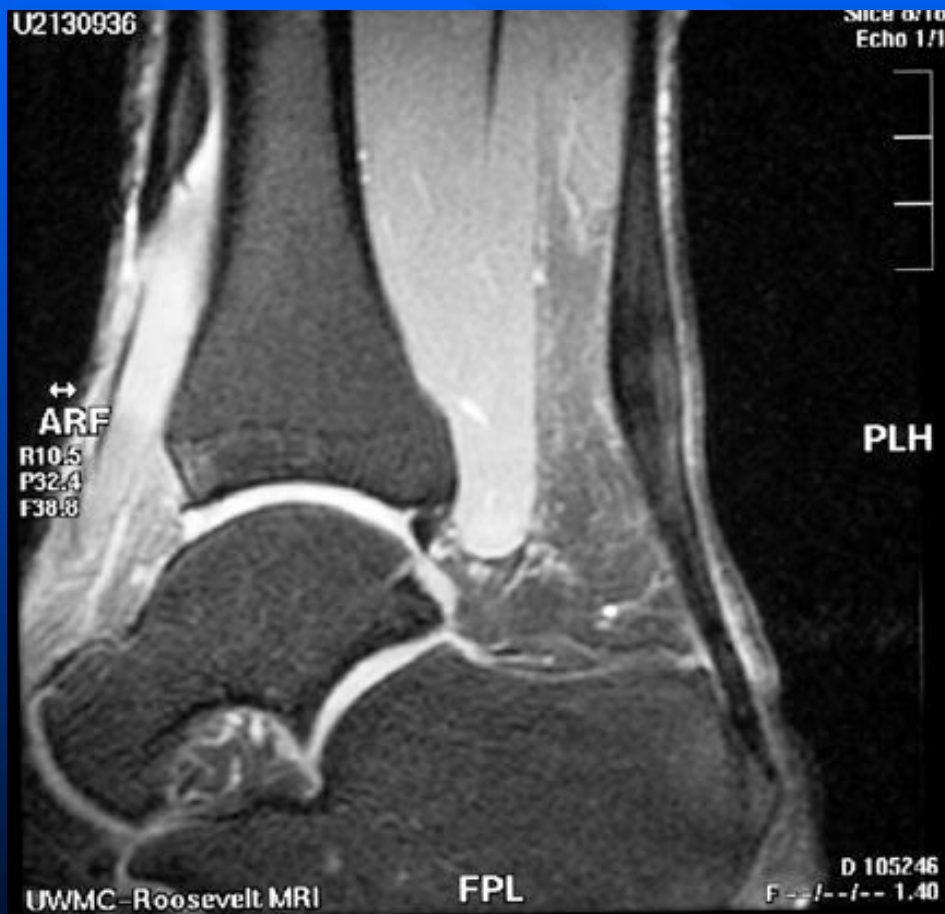

**Acute achilles tendon rupture:** These typically occur about 6cm above the insertion



Has No tendon sheath

# Achilles tendonopathy



# Ankle

- Plantaris tendon is anterior and medial to achilles and is present 90% of the time
- High signal plane between the 2 can mimic tear
- Can mimic remaining fibers in complete tear.