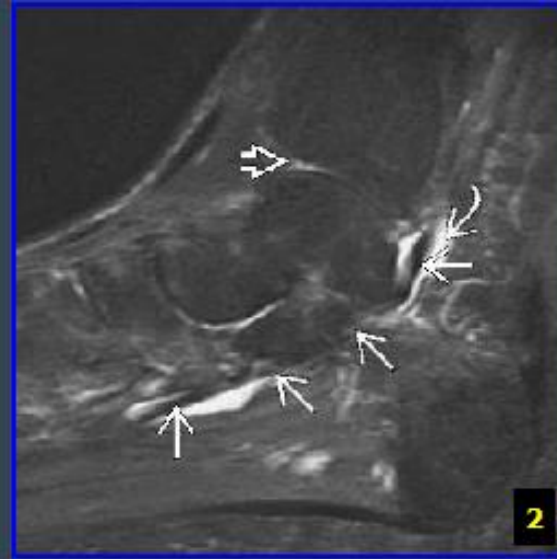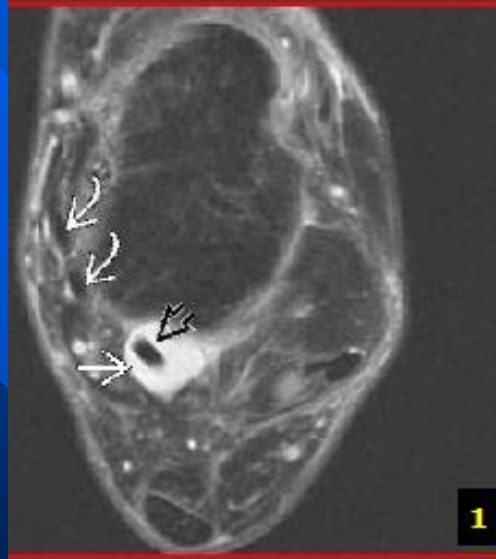
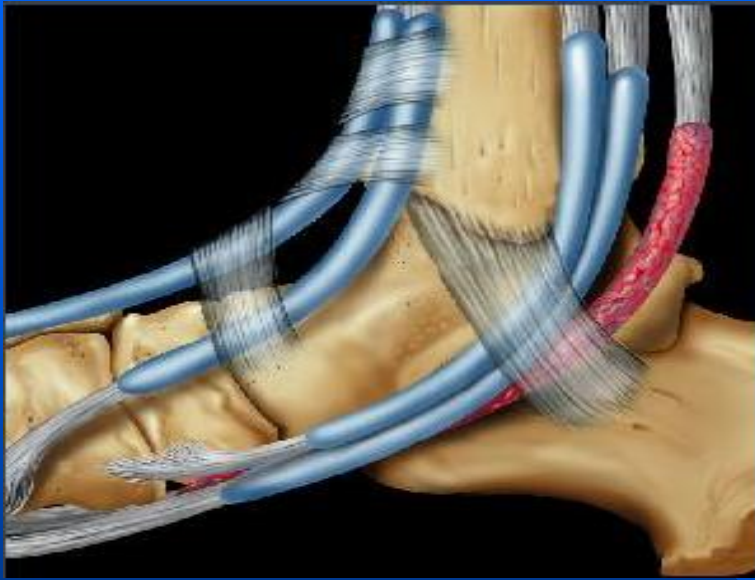


# Flexor Hallucis Longus Tendon

- Communicates with ankle joint 20% of the time
- If fluid in ankle joint, fluid can be around tendon and be of no consequence.
- Tears are uncommon, tenosynovitis is much more common.

# Tenosynovitis



# Tenosynovitis

- Best diagnostic clue: Hyperintense fluid (FS PD FSE) in synovial sheath disproportionate to quantity of tibiotalar joint fluid
- **Pathology**
  - Repetitive plantar flexion and dorsiflexion lead to tenosynovitis
  - Twisting injury ankle
  - Paratendinitis (tenosynovitis) most common abnormality

