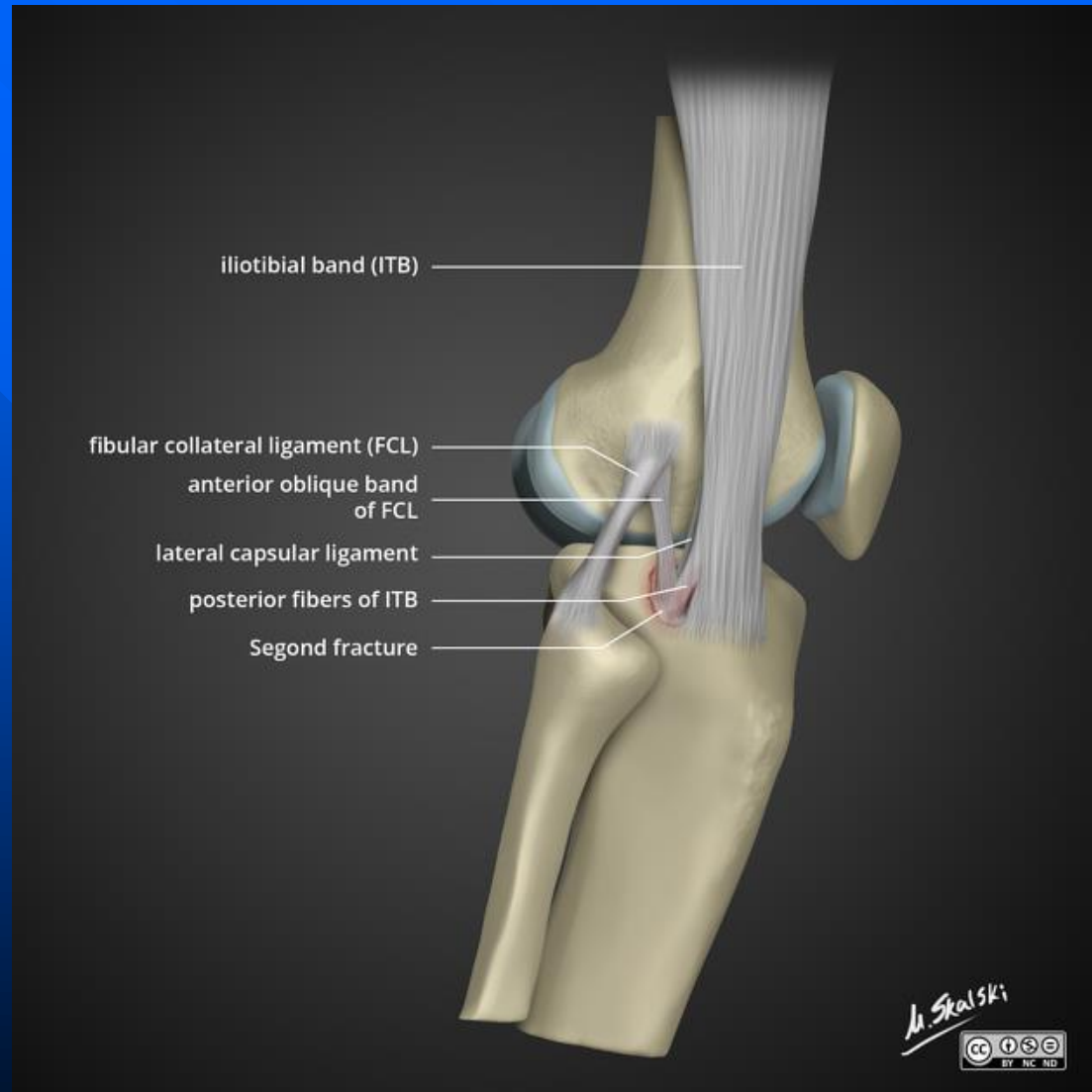
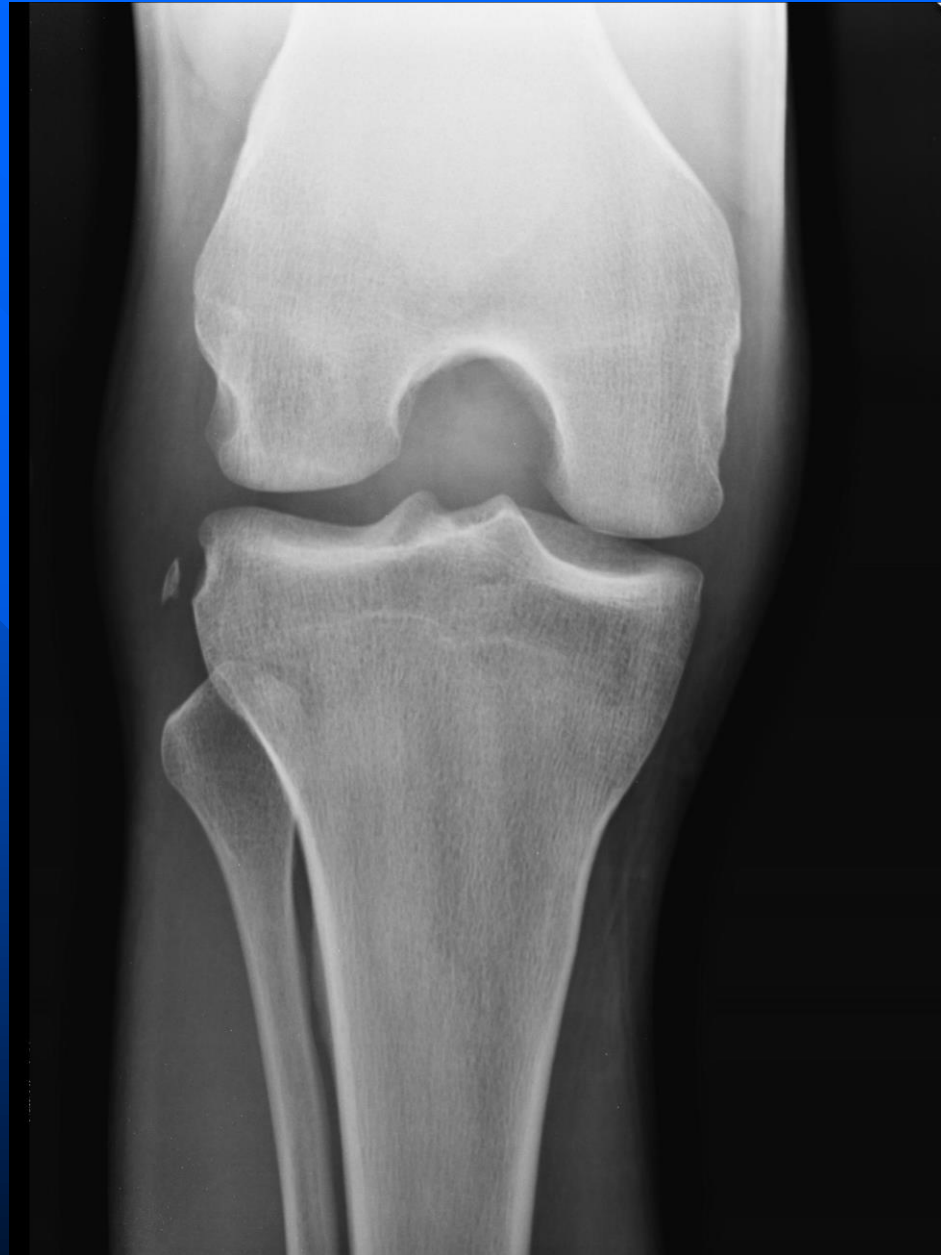
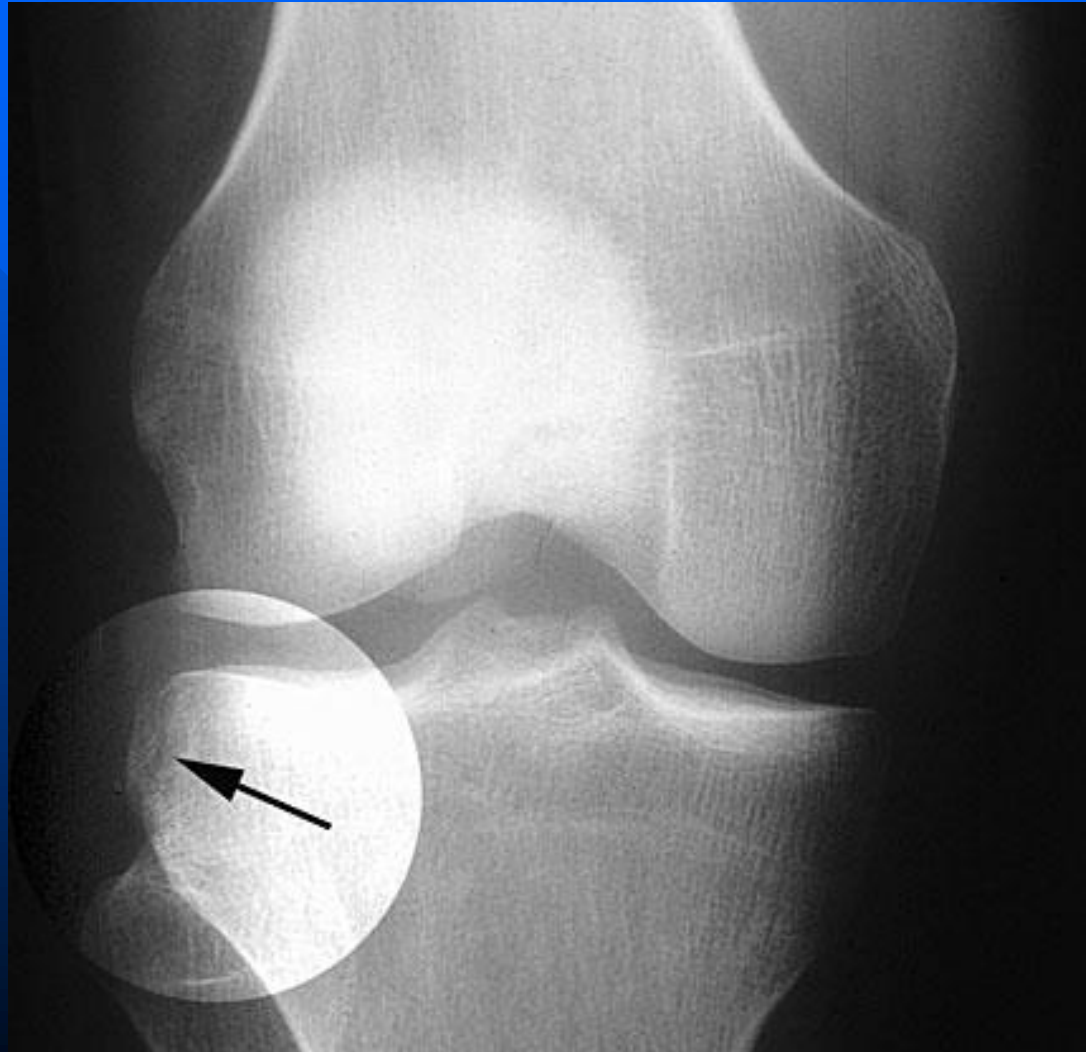
Segond fracture

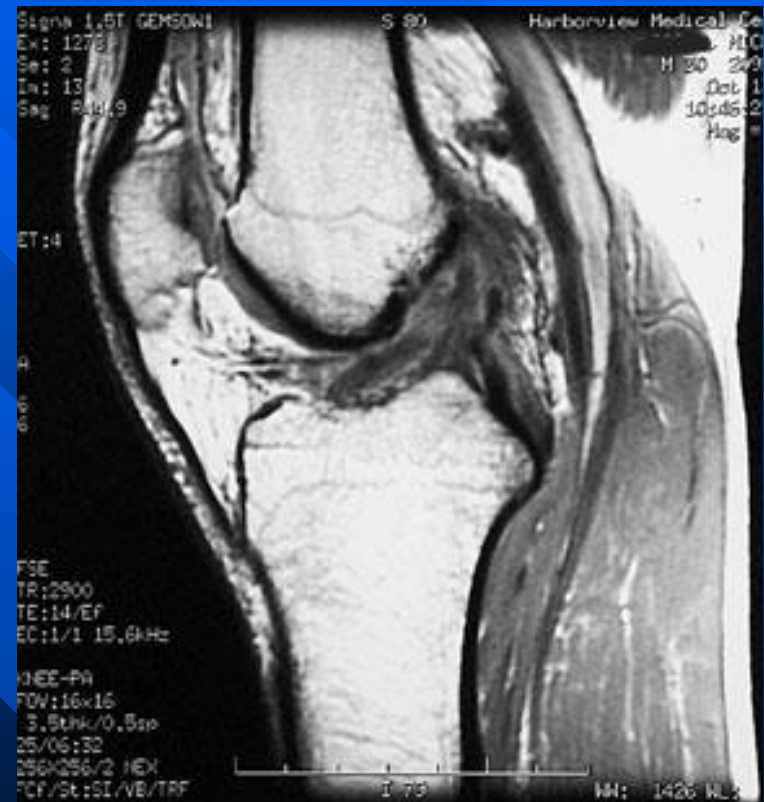
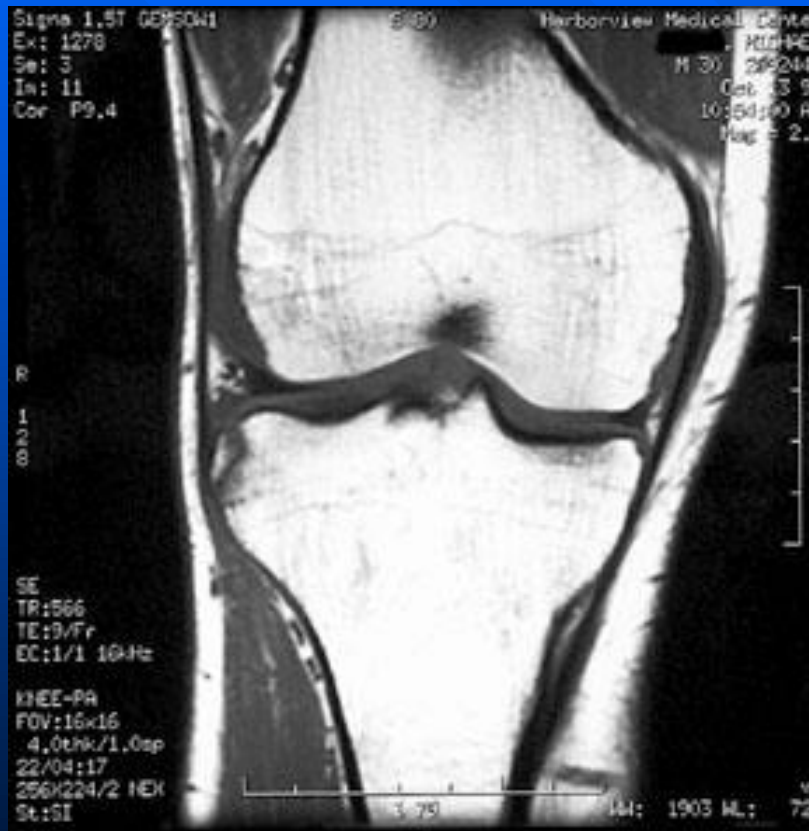


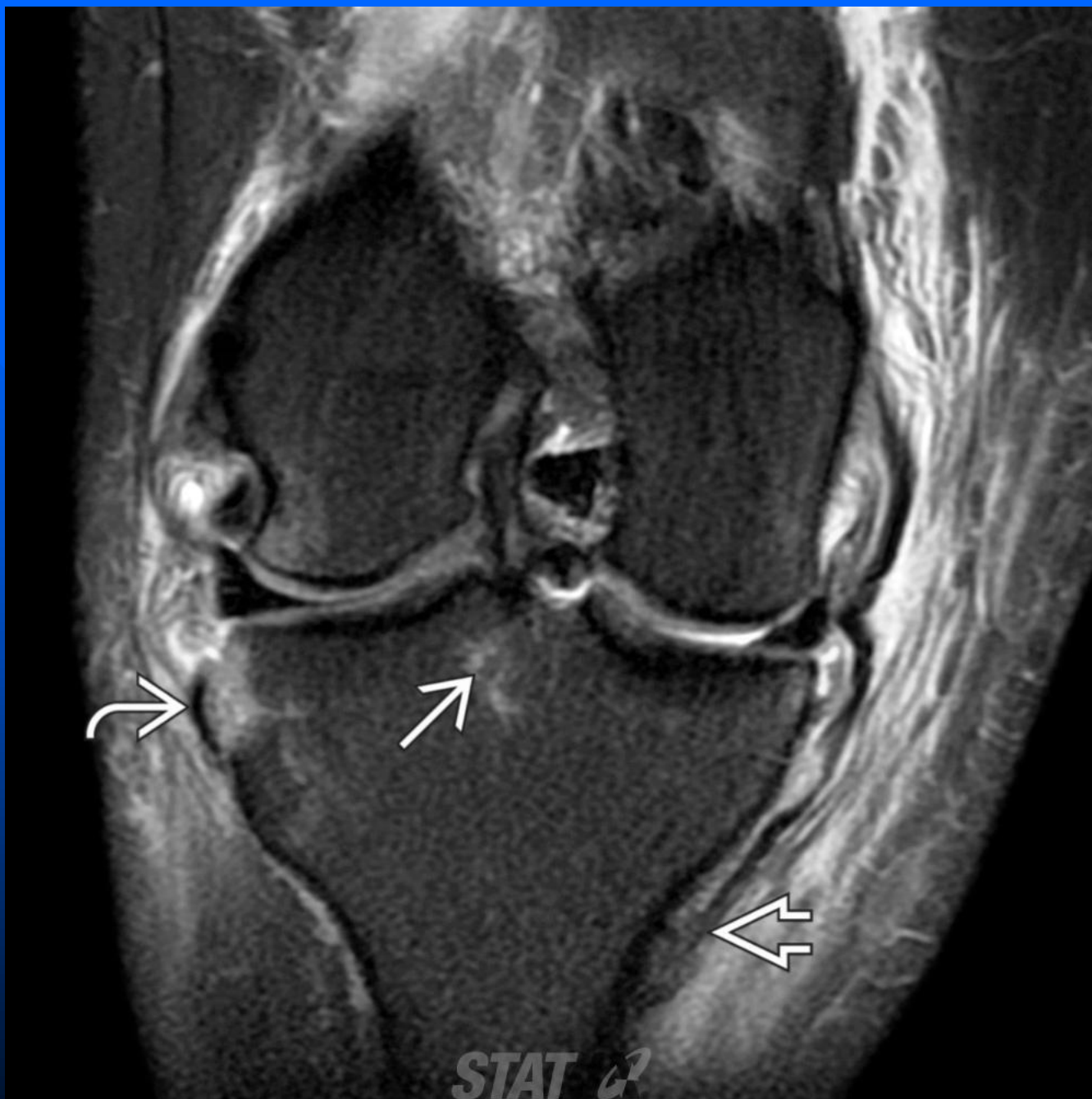Segond fracture



Second fracture (lateral capsular avulsion) with ACL tear





Coronal T2WI FS MR from the same patient shows the Second avulsion (white curved arrow), as well as disruption of the distal medial collateral ligament (white open arrow). The ACL avulsion (white solid arrow) is partially seen, located more anteriorly.