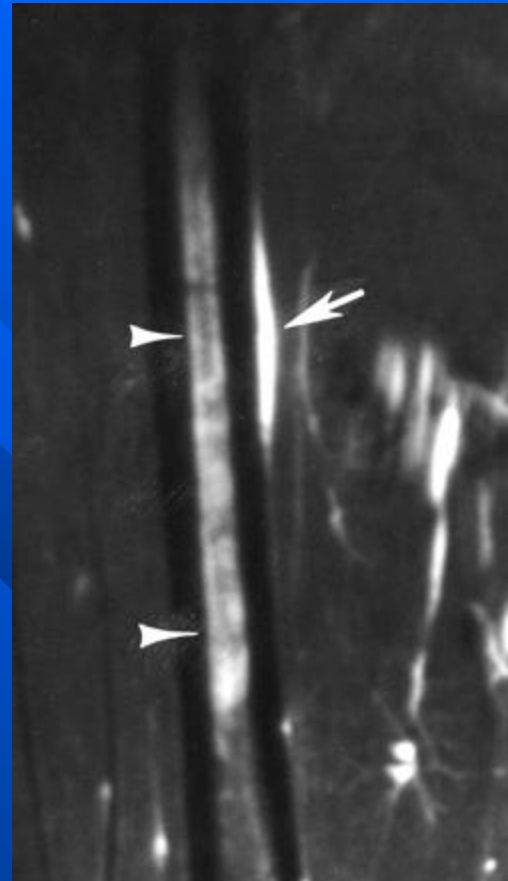


Thigh splints

- High signal intensity along periosteum of proximal to mid femur (*arrow*)
- Associated medullary signal intensity abnormality (*arrowheads*).



Thigh splints

