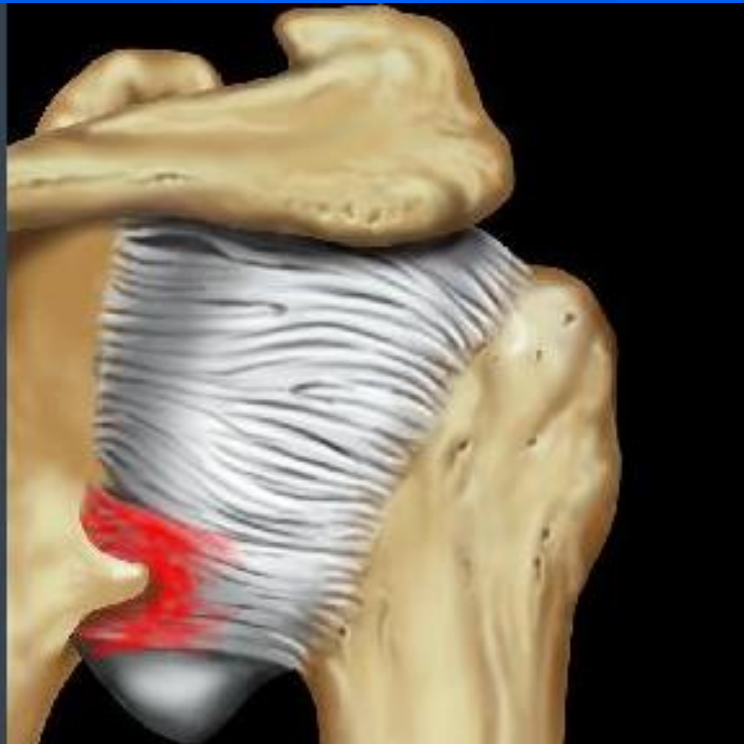

Bennet lesion

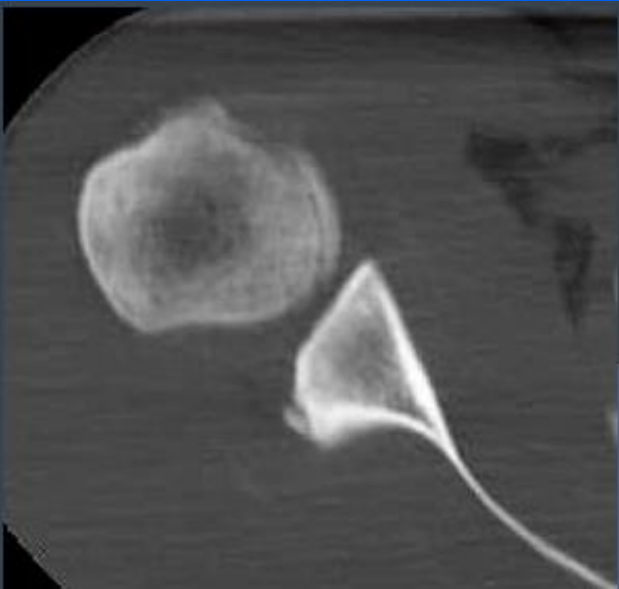
- Is an extra-articular posterior ossification associated with posterior labral injury.
- Thought to be due to posterior capsular avulsion secondary to traction from the posterior band of the IGHL.
- Commonly seen in pitchers

Bennet lesion

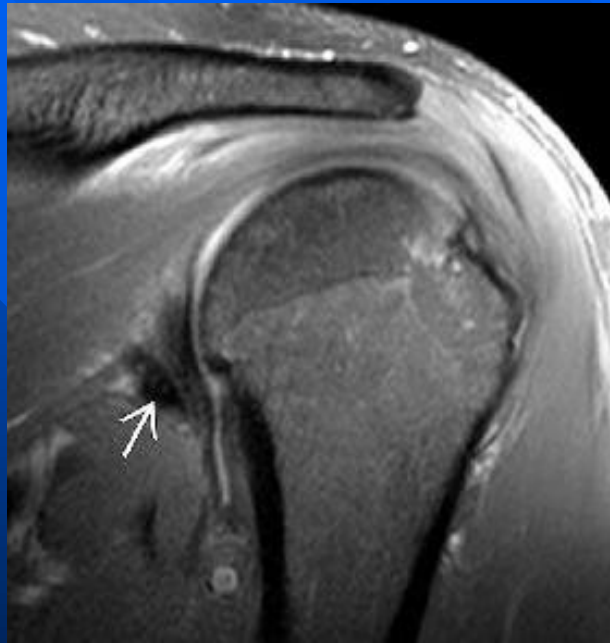


- Best diagnostic clue
 - Globular hypointense ossification on T1 & T2WI
 - Adjacent to torn or degenerated posterior labrum

Bennet lesion “Baseball pitcher”



heterotopic ossification
posterior to the
posteroinferior glenoid.



hypointense,
heterotopic ossification
(arrow) posterior to the
posteroinferior glenoid.

