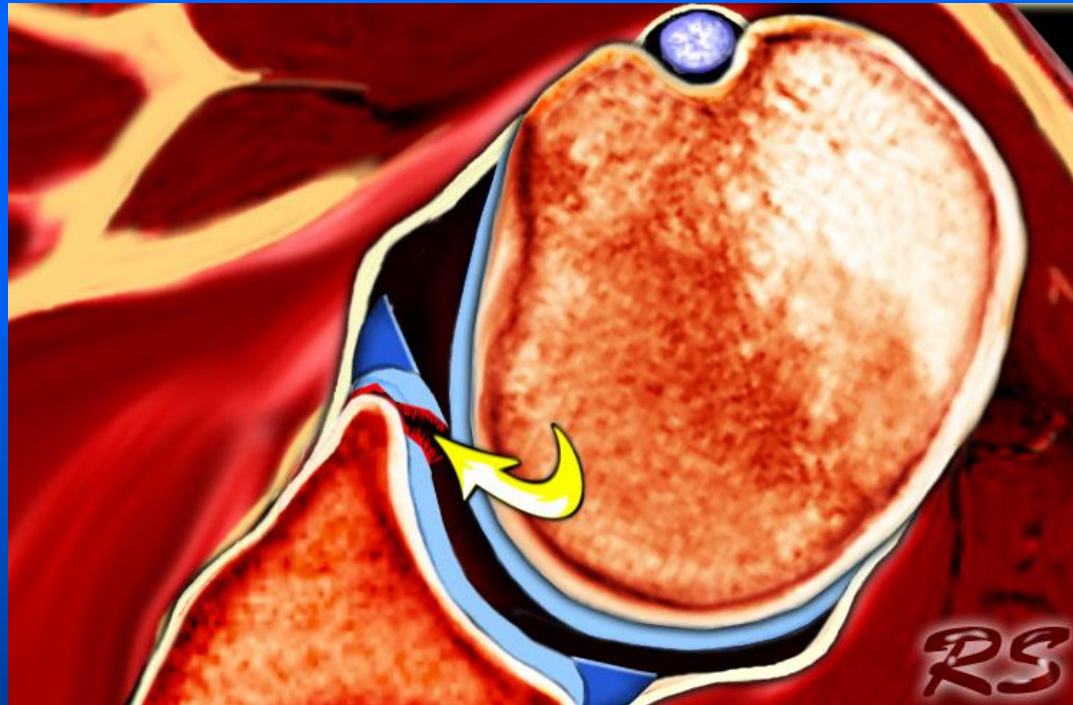
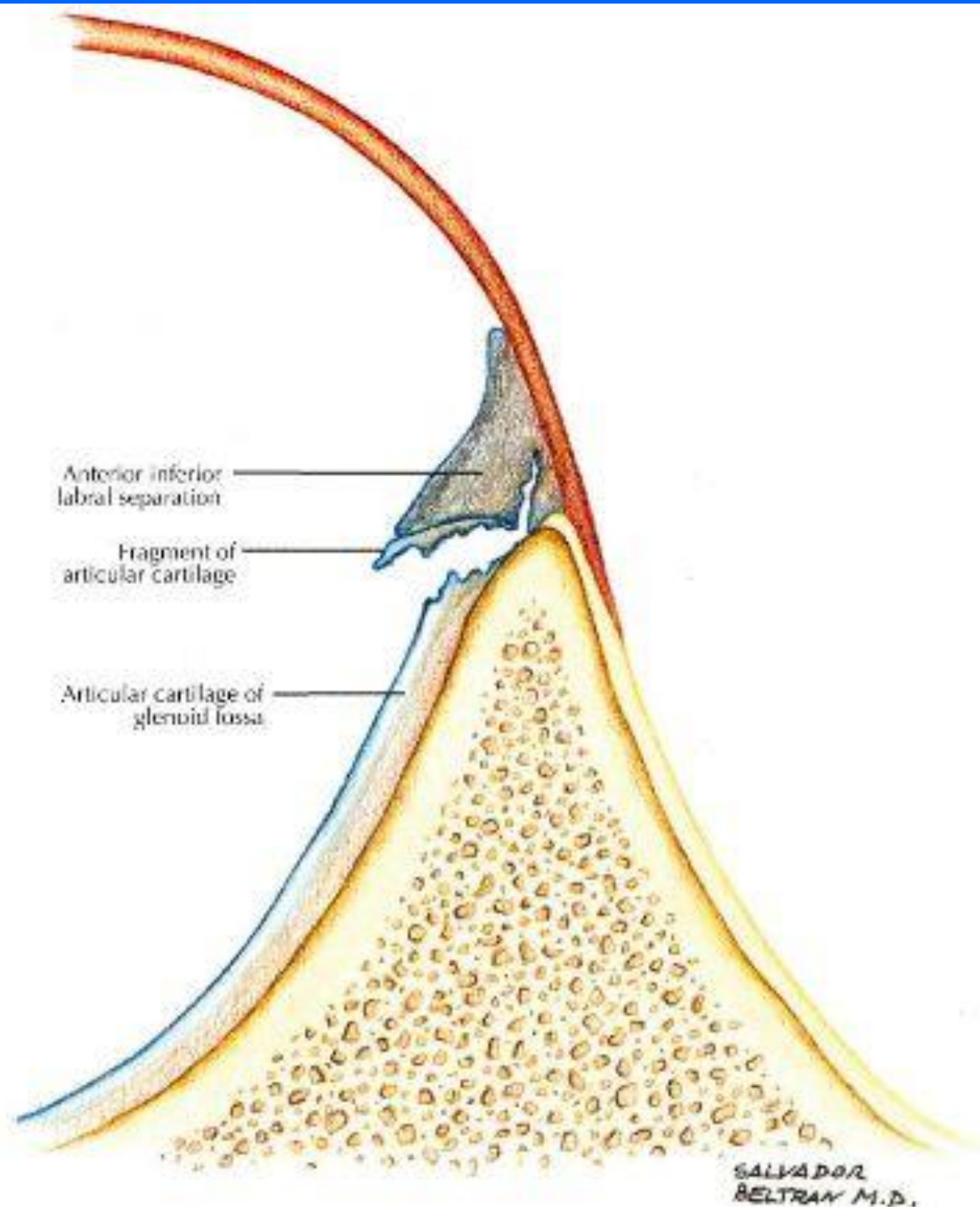


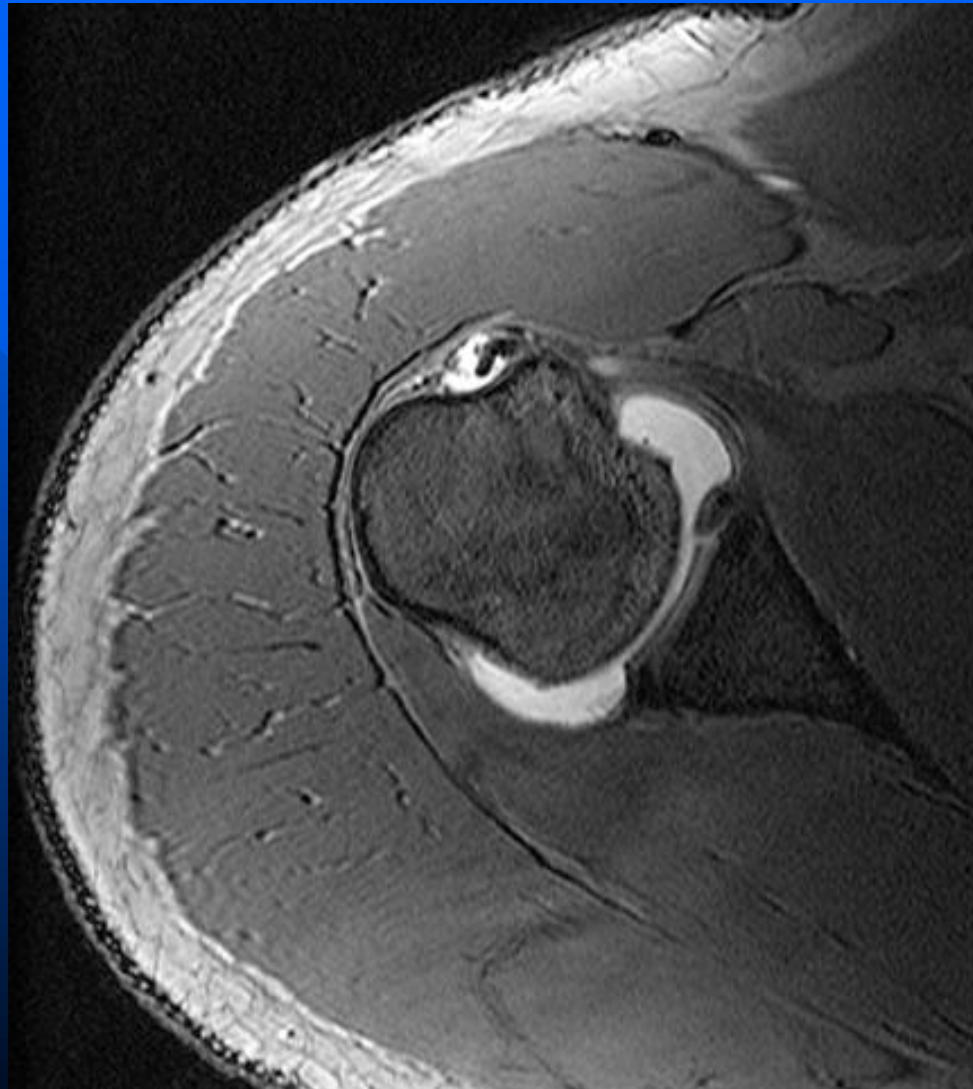
GLAD lesion



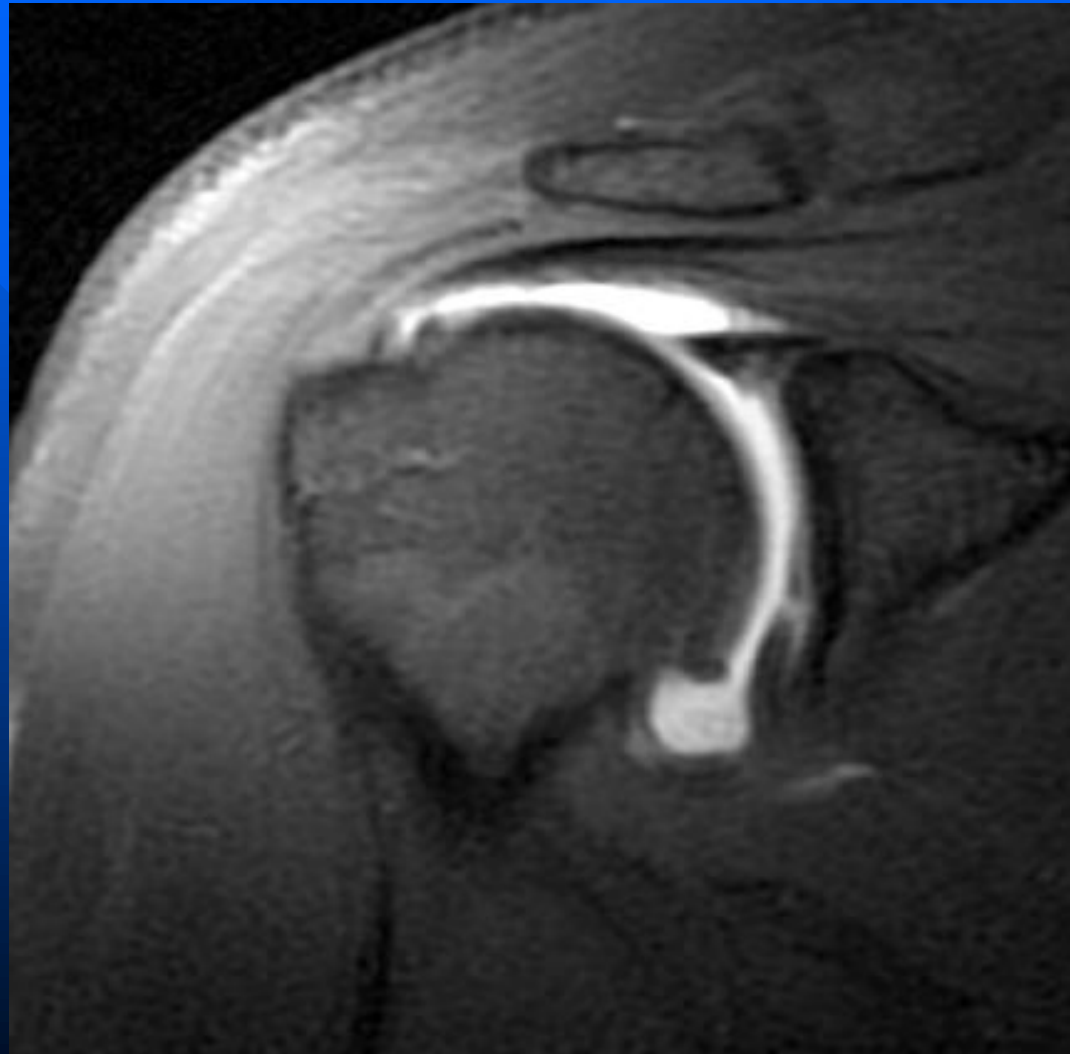
- Glenolabral articular disruption
- This lesion consists of an anterior-inferior labral tear associated with an injury to the glenoid articular cartilage



Glad Lesion



Glad Lesion



Glad

