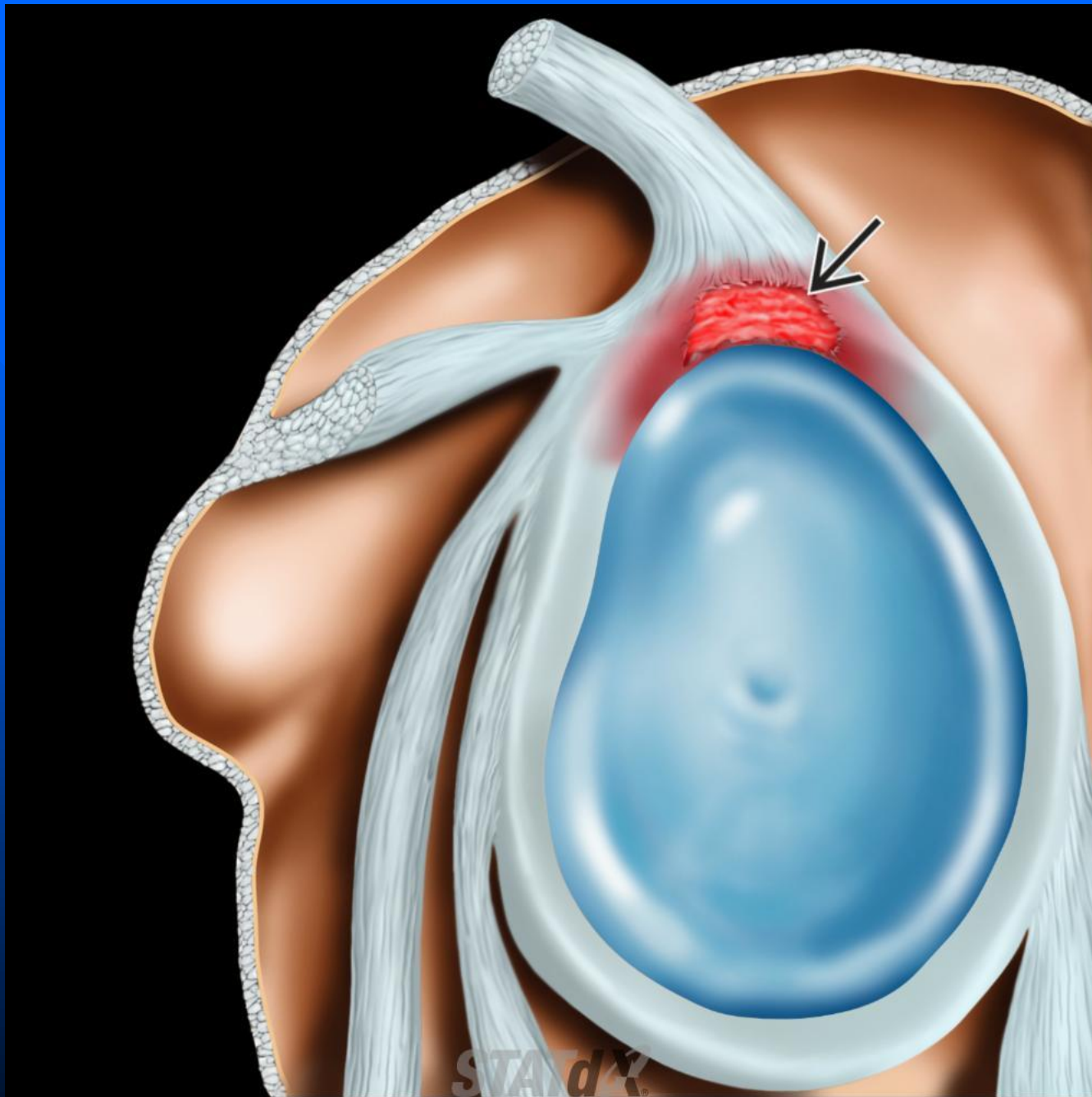
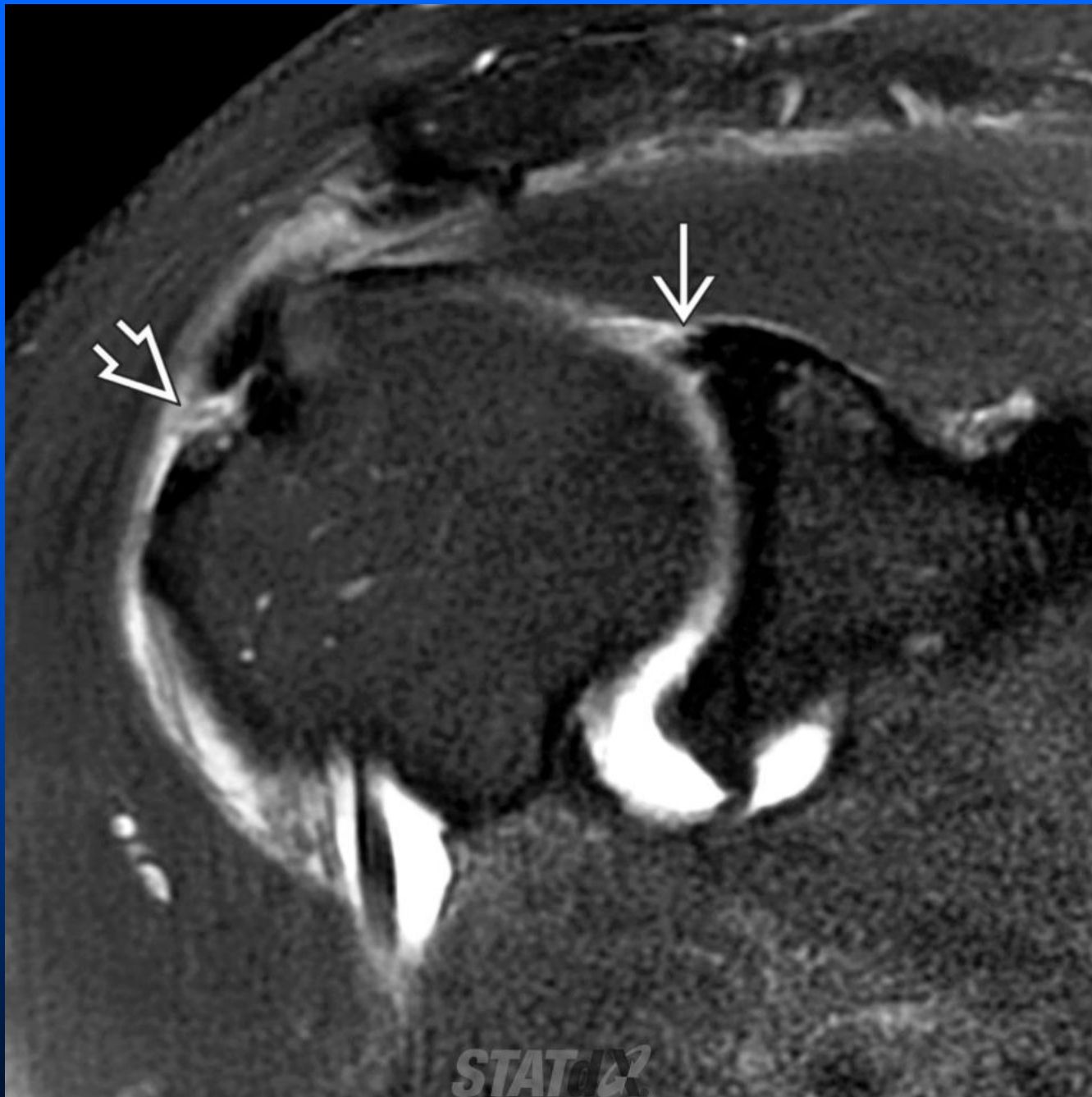


Type 1 Tear

- Irregular fraying of tip of superior labrum
- Common age related finding (degenerative)
- > 50 years old
- 75% are type 1
- May also have myxoid degeneration within substance of labrum
- Usually asymptomatic and do not require treatment
- Treat conservatively



Lateral graphic shows a type I superior labrum anterior and posterior (SLAP) tear. There is superficial fraying of the superior labrum (black solid arrow) without a deep tear. Type I SLAP tears are common (20% of all shoulder arthroscopies), and the biceps anchor is stable.



Coronal oblique T1 FS MR arthrogram shows a type I SLAP tear with fraying of the superior labrum (white solid arrow). There is also a rotator cuff tear (white open arrow).