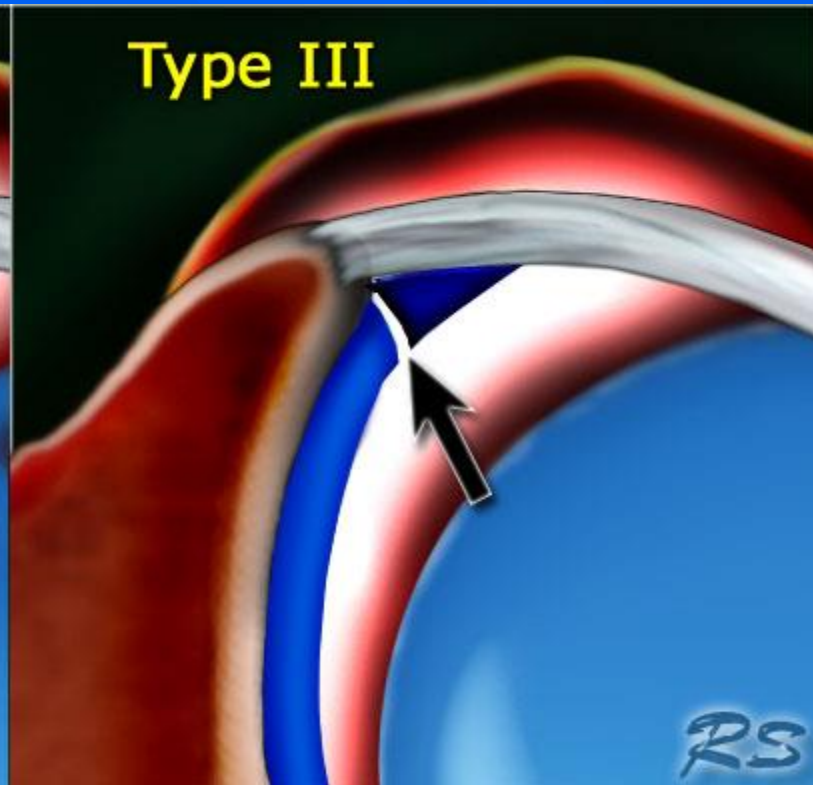
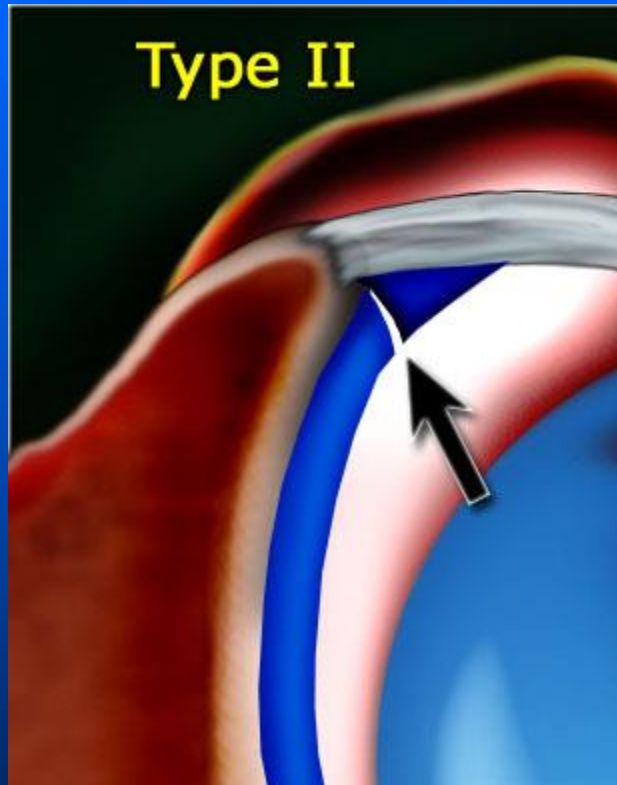
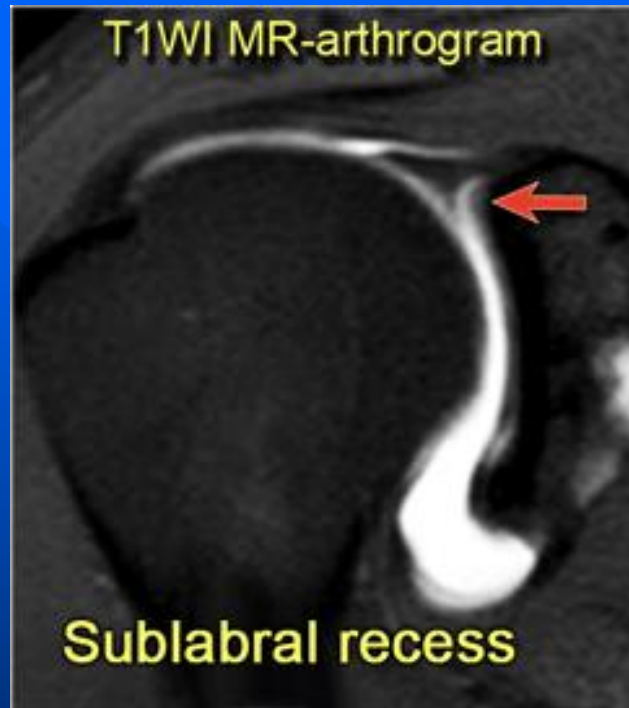

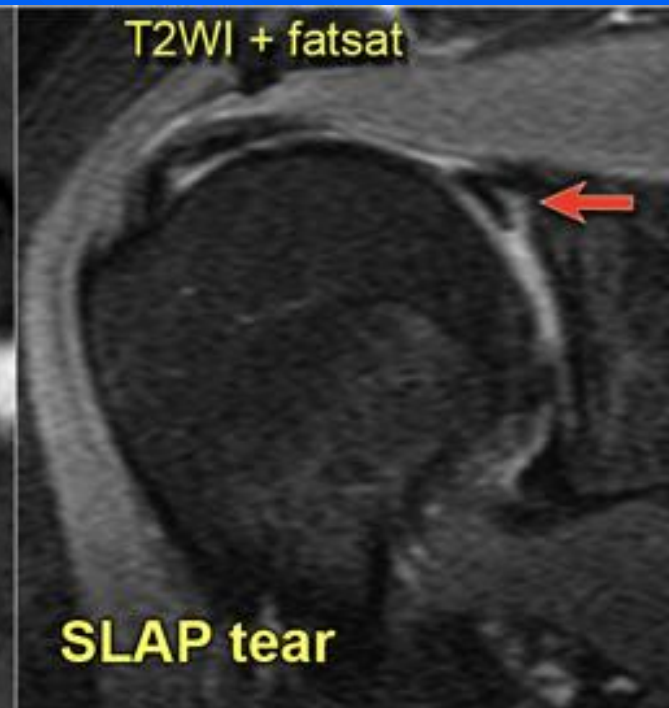Sublabral recess

- 3 types of attachment of the superior labrum at the 12 o'clock position where the biceps tendon inserts.
- Type I there is no recess between the glenoid cartilage and the labrum.
- Type II there is a small recess.
- Type III there is a large sublabral recess.
- This sublabral recess can be difficult to distinguish from a SLAP-tear or a sublabral foramen.





- High signal extends medially and follows the contour of the glenoid cartilage
- Smooth margin
- < 3mm
- Located at biceps anchor



- High signal extending laterally
- Irregular margin
- Can be > 3mm
- Located at biceps anchor and posteriorly

