

Anatomy

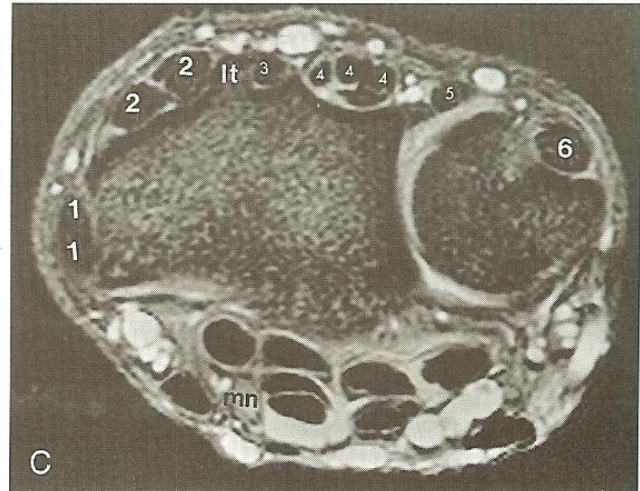
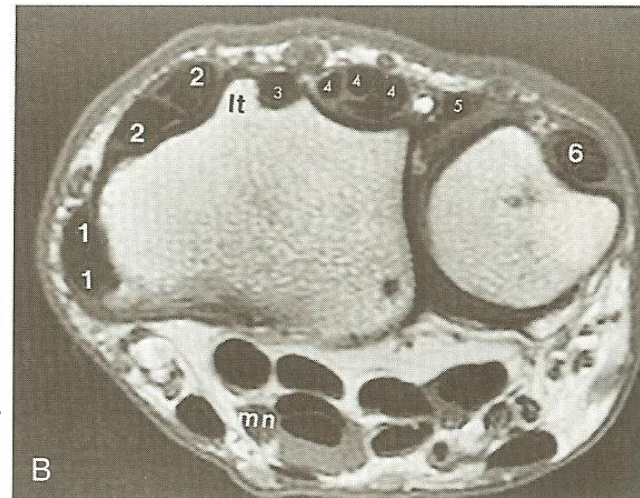
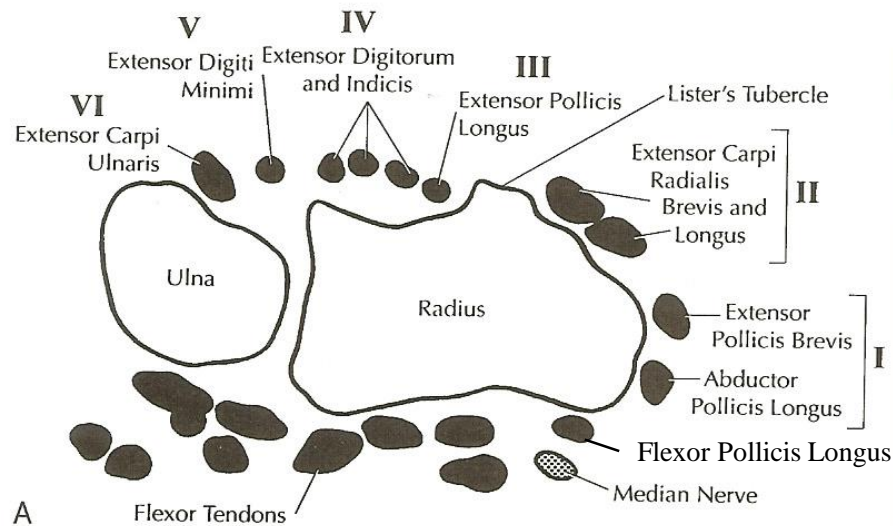
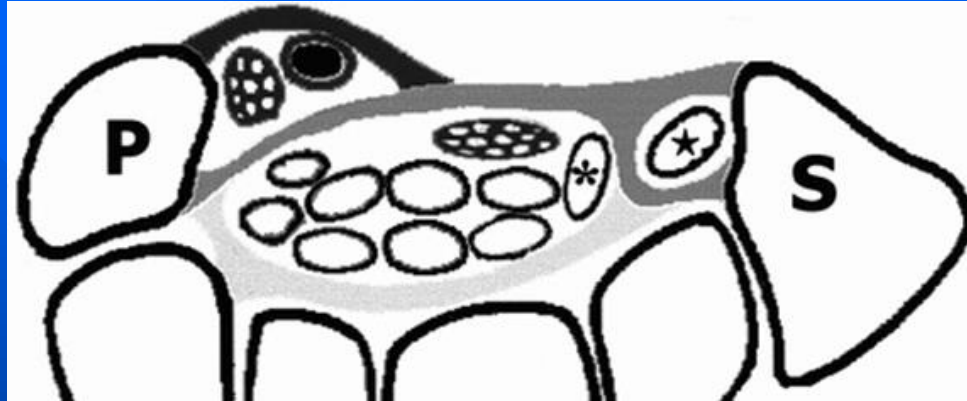

Figure 12-19. NORMAL TENDONS OF THE WRIST.

A, Diagram of the wrist in the axial plane at the level of the distal radioulnar joint (DRUJ). This shows the six dorsal compartments that contain the tendons, which are labeled. The flexor tendons and median nerve are present volarly. **B**, T1 axial image, wrist through the DRUJ. The dorsal tendons are labeled with numbers that correlate with the dorsal compartments shown in the diagram in **A**. mn—median nerve; lt—Lister's tubercle. **C**, T2* axial image, wrist through DRUJ. The dorsal tendons are labeled as in **B** to correspond to the six dorsal compartments in the diagram in **A**. mn—median nerve; lt = Lister's tubercle.

Anatomy

Ulnar Side



Radial Side

