

# Primary Bone Lymphoma

- Primary bone (skeletal/osseous) lymphoma (PBL) is a less common manifestation of lymphoma than secondary involvement from disseminated lymphoma.
- It is rare, accounting for <5% of bone tumors and <1% of non-Hodgkin lymphoma.
- PBL is defined as the presence of lymphoma isolated to one bone without distant spread for six months after diagnosis.
- Multifocal PBL is less common and occurs with lymphoma is confined to two or more bones, again without distant spread for six months

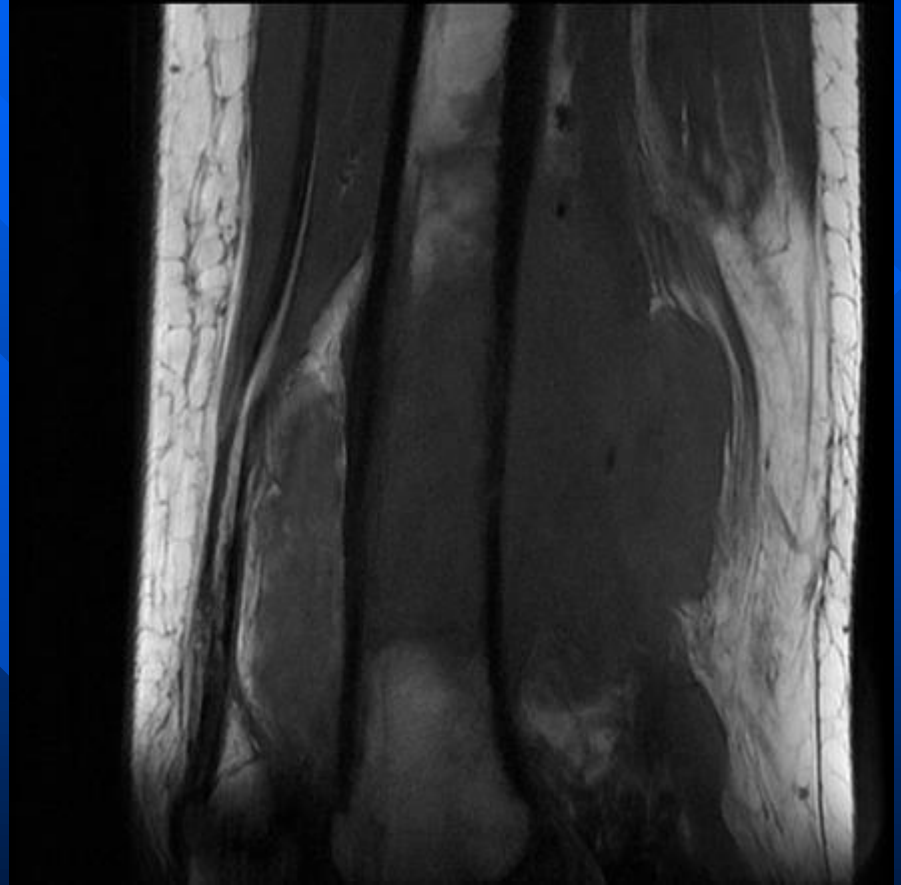
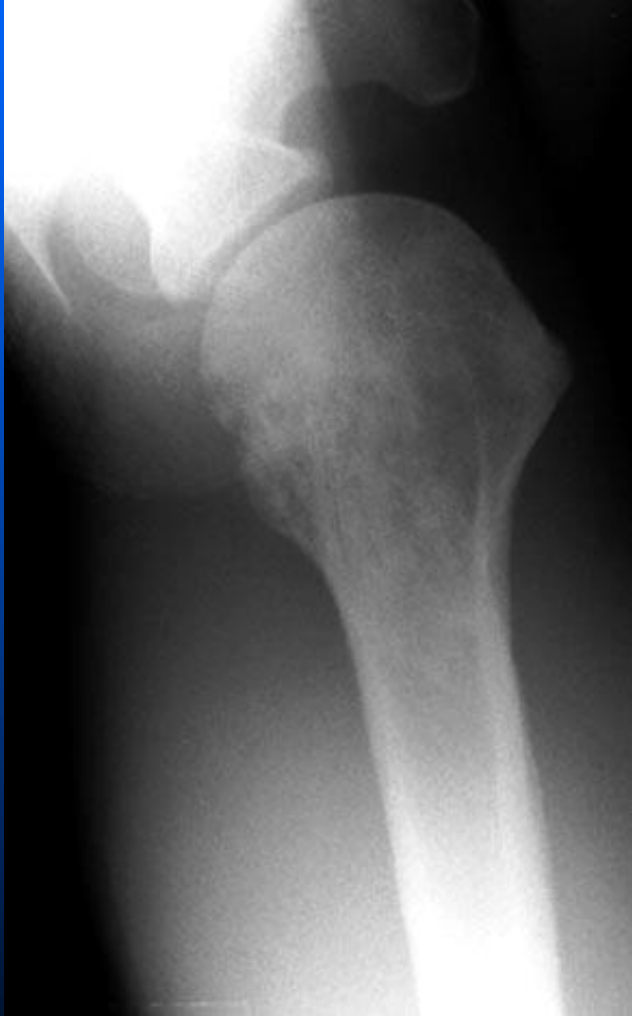# Lymphoma

- Can affect any age group, with peak incidence in (50-60) year-olds.
- Rare in children <10 years old.
- Slight male predominance
- The bony **pelvis and femur** are the most common locations.
- In adults, it usually occurs in regions of persistent red marrow

# X-ray

- Non-specific features and the affected bone may be normal or affected by lytic, sclerotic or mixed pattern.
- Most common is a lytic pattern with **permeative bone** destruction and a wide zone of transition.
- Cortical thickening and periosteal reaction may also be seen.

# Lymphoma



# Lymphoma

