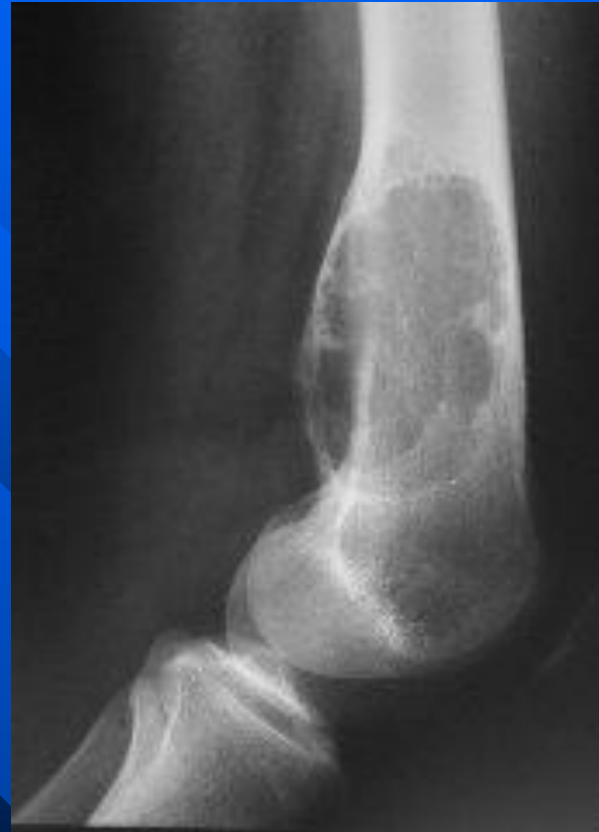
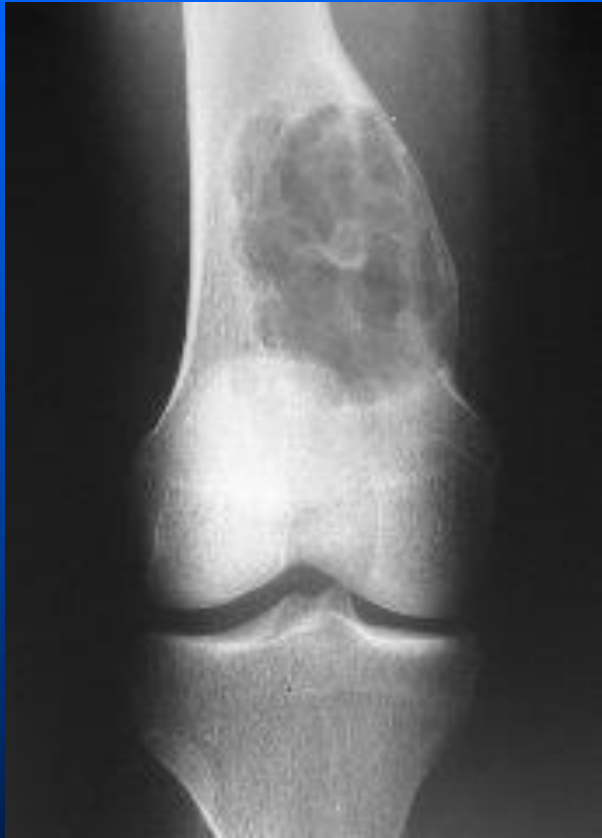
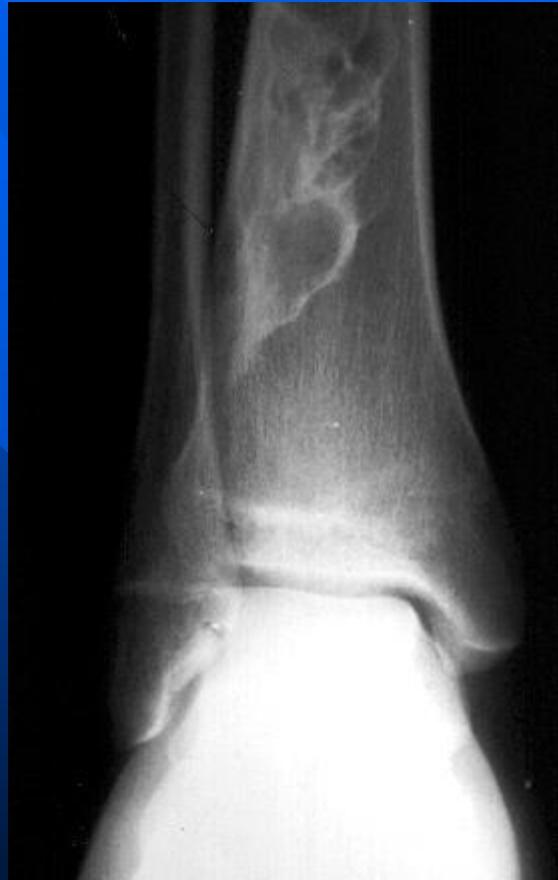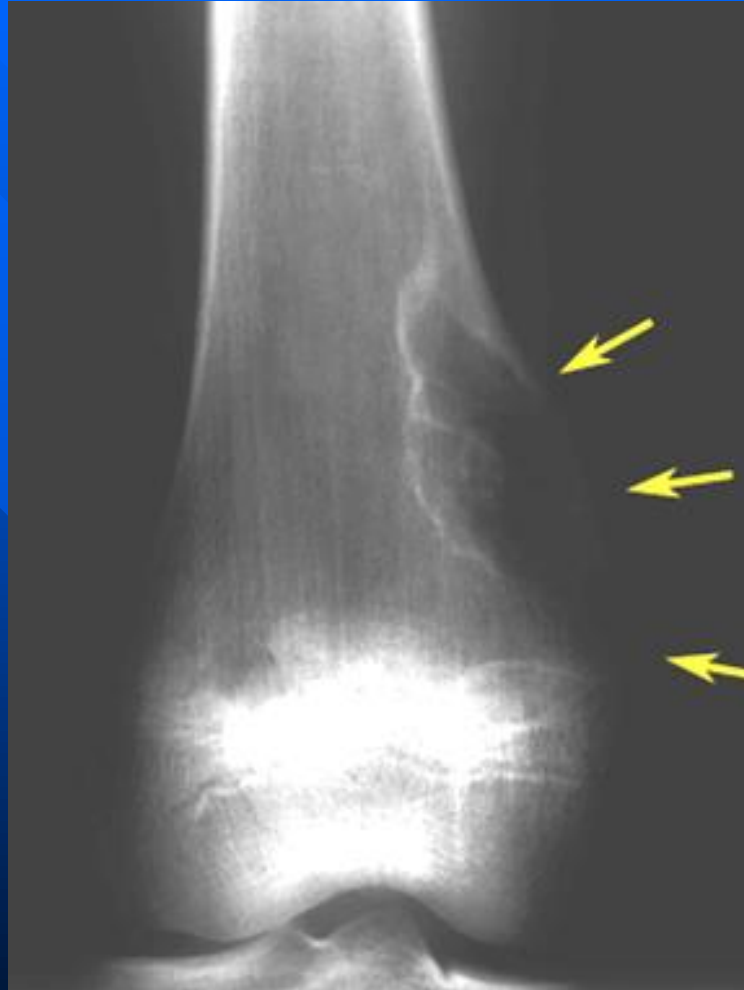
Fibroxanthoma



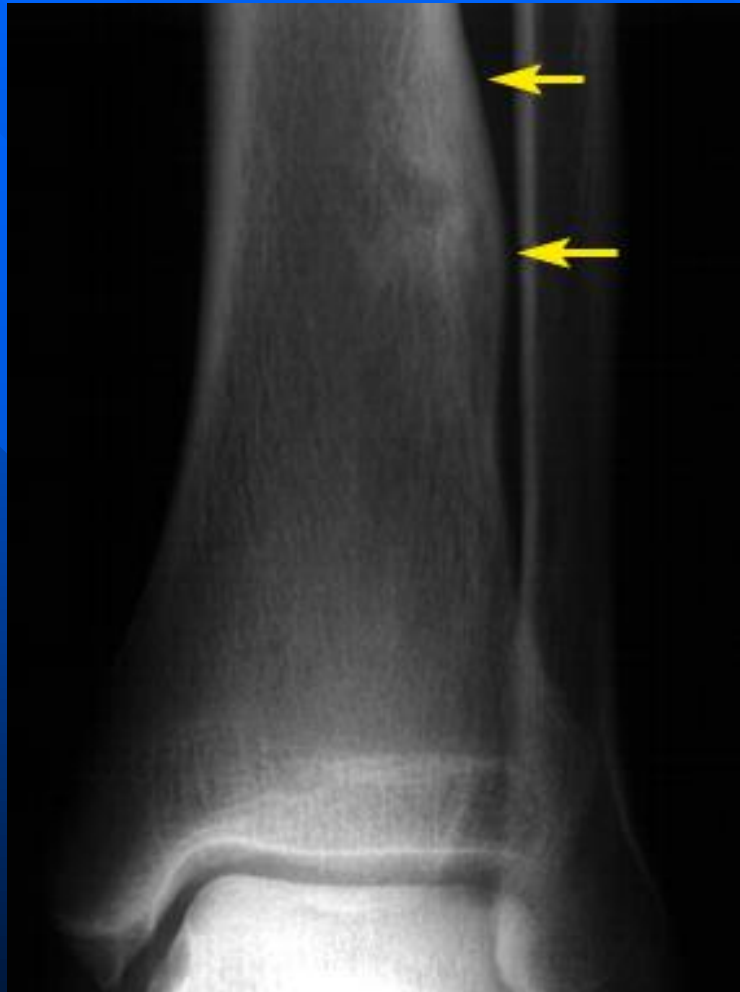Fibroxanthoma



NOF



Healing non-ossifying fibroma



NOF > 1.5 cm

Fibroxanthoma

- Seen in metaphysis
- Appear to migrate from the physis
- Cortical well defined lucent lesion
- Associated with rickets and chondromalacia