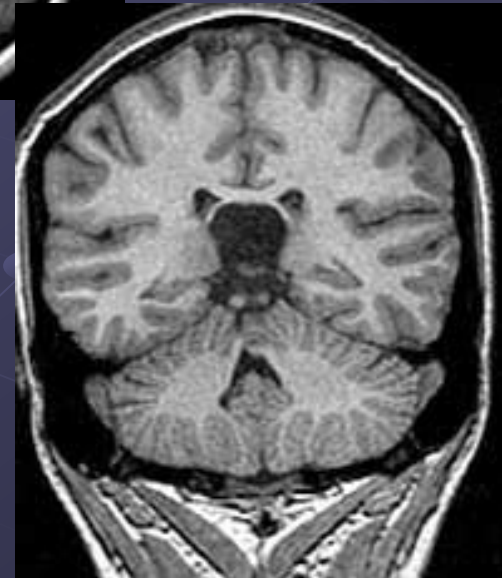
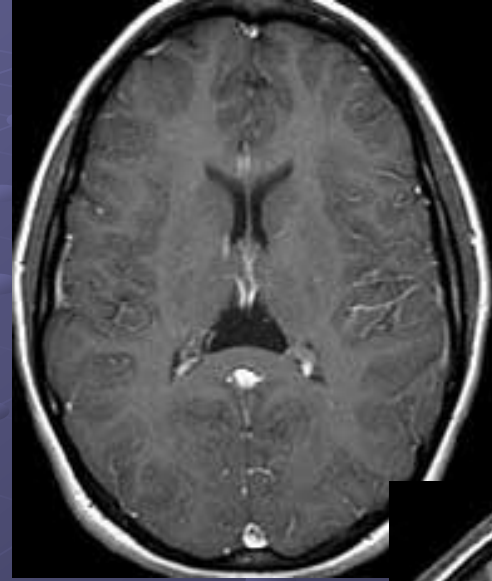
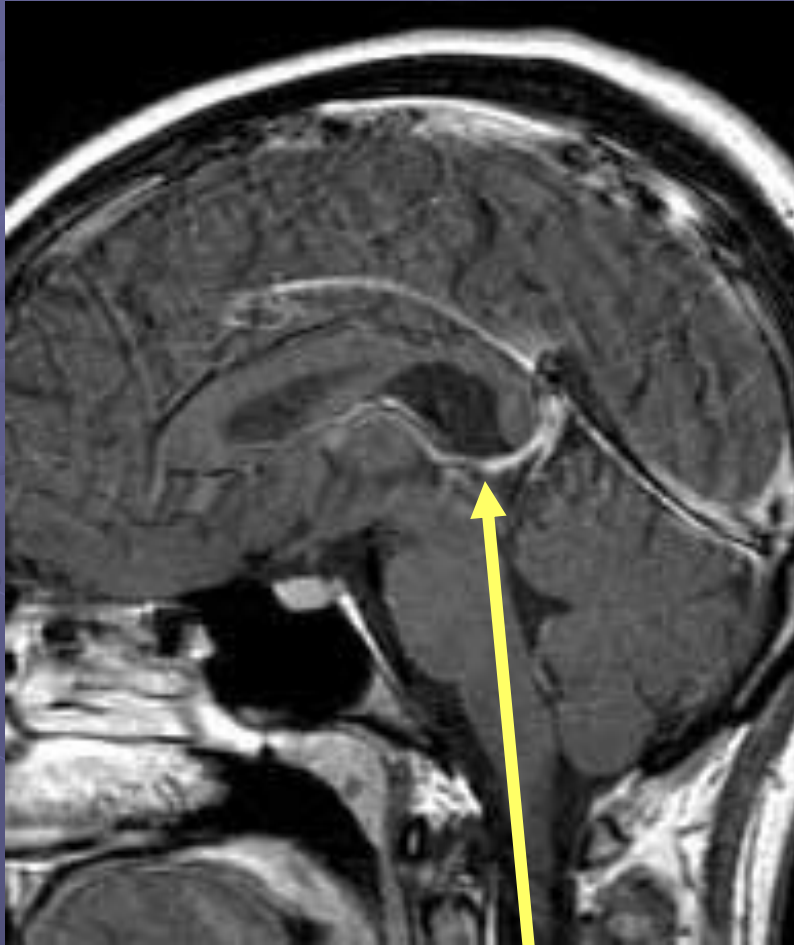


Cavum velum interpositum



Cavum velum interpositum - is above internal cerebral veins and will displace veins inferiorly.

Cavum velum interpositum

- Often detected incidentally and individuals are usually asymptomatic.
- Sometimes this space is not only visible but expanded as a cystic space, in which case patients may have symptoms relating to altered CSF flow (obstructive hydrocephalus leading to a headache).
- Unlike the cavum septi pellucidi and cavum vergae, a cavum veli interpositi has not been associated with neurophyschiatric disorders

