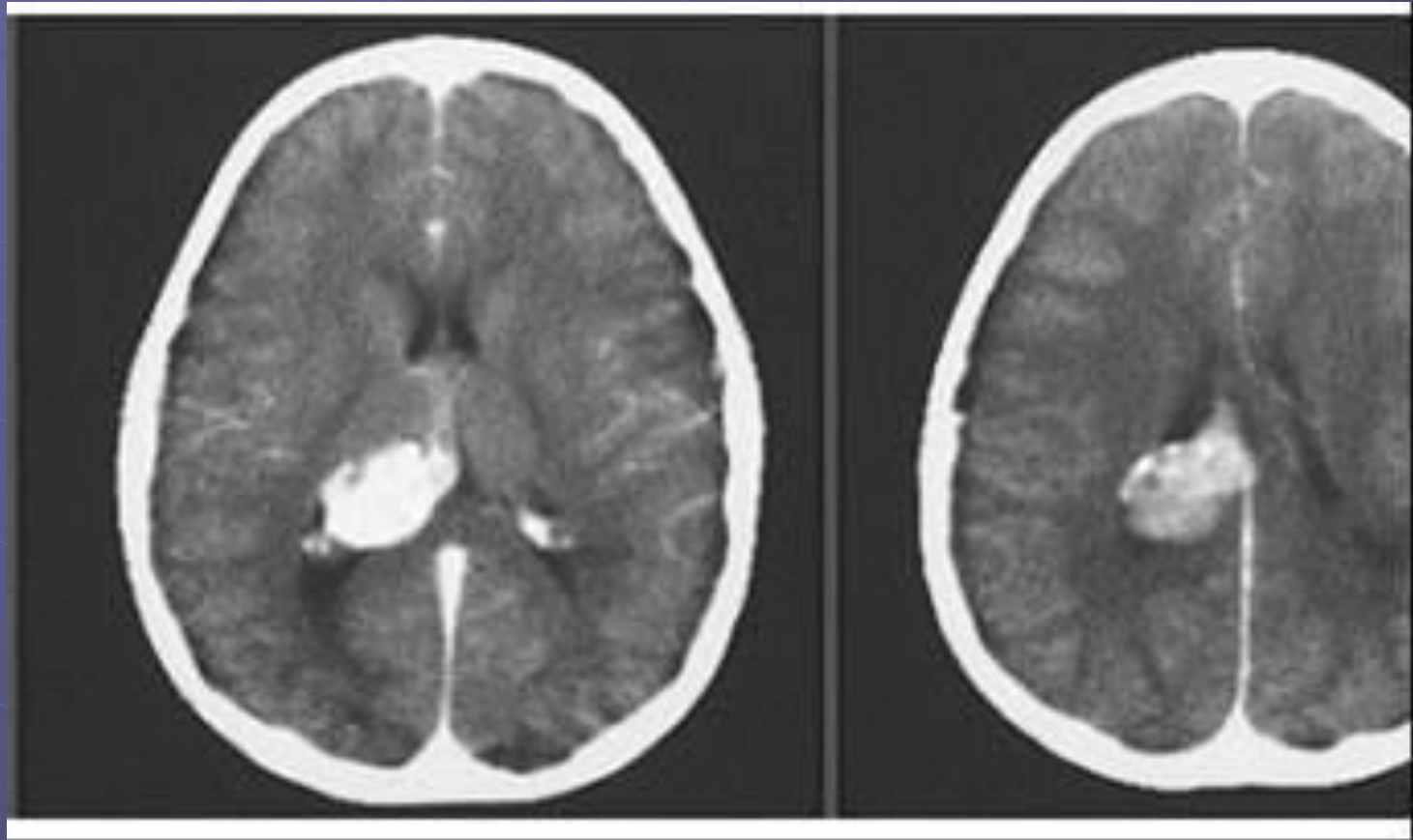


# Intraventricular meningioma in child



# Adult (3<sup>rd</sup> vent)

