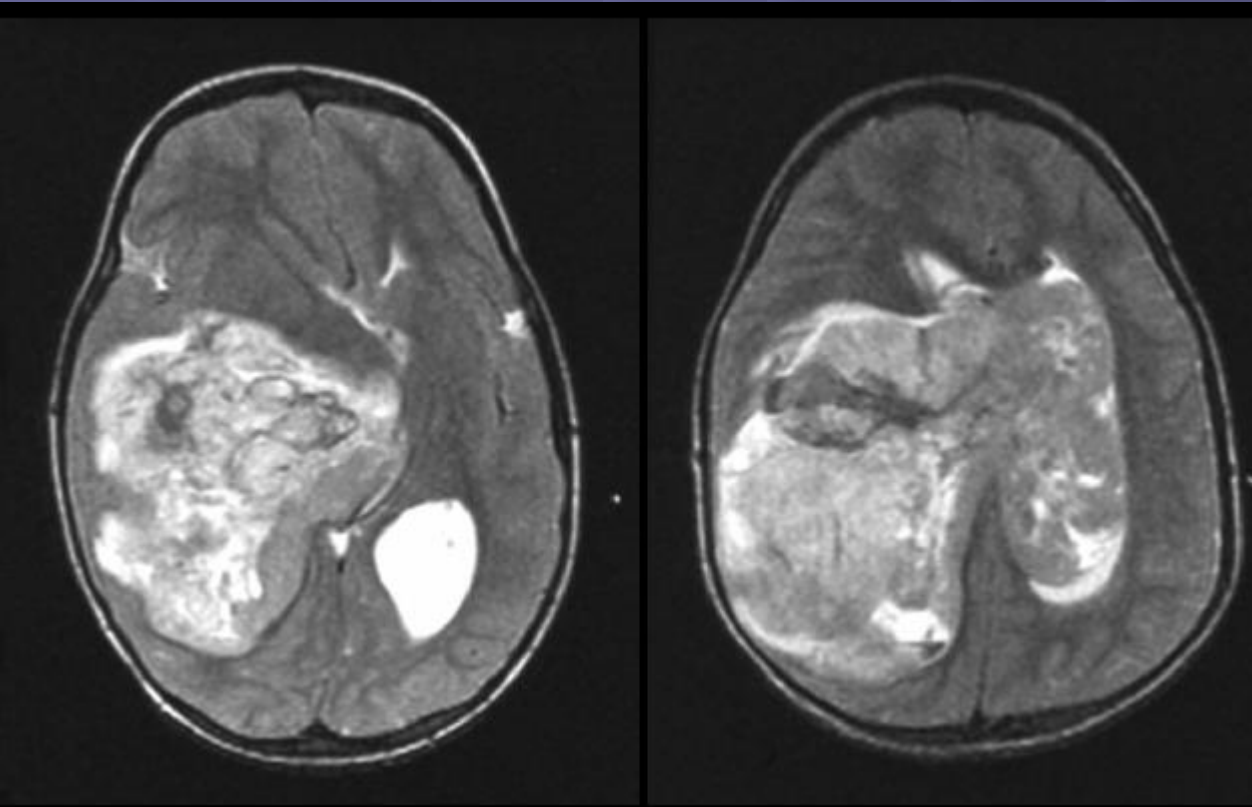


Intraventricular PNET



● DDX:

- Choroid plexus carcinoma
- Ependymoma
- atypical teratoid / rhabdoid tumor

PNET

- Supratentorial PNETs are typically located in the cerebral hemisphere or lateral ventricle
- Highly malignant primary neoplasms of the central nervous system (CNS), which occur primarily in children.

General Features

- Best diagnostic clue: Strongly enhancing, lobulated intraventricular mass
- Location
 - 70% atrium of lateral ventricle, left > right
 - 20% fourth ventricle
 - Most common site of origin in adults