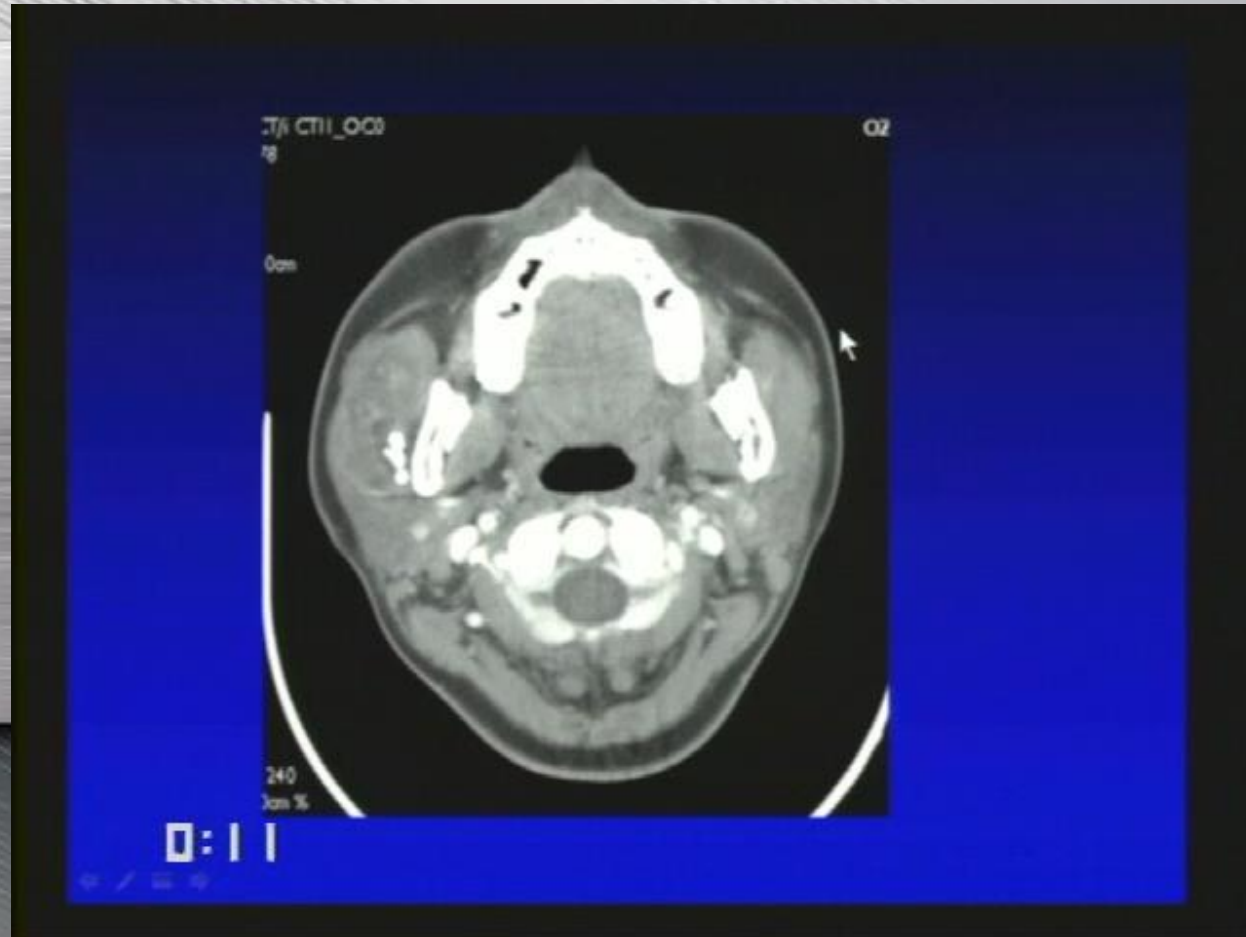
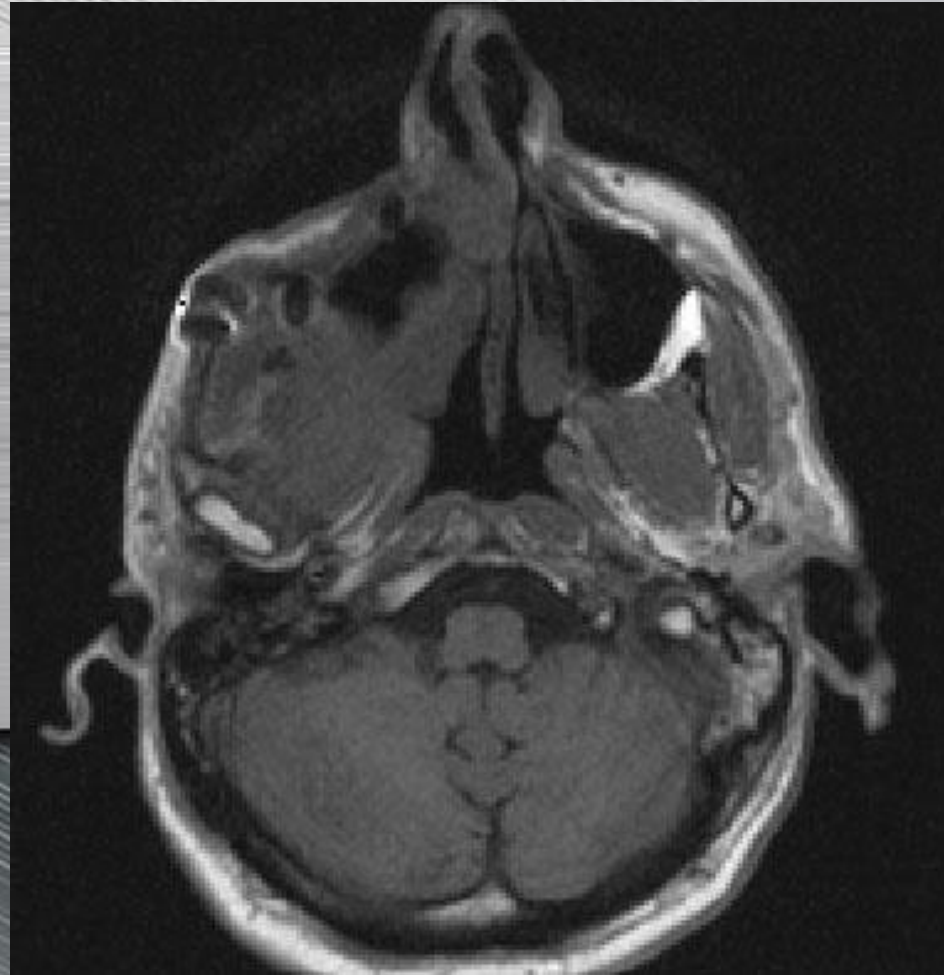


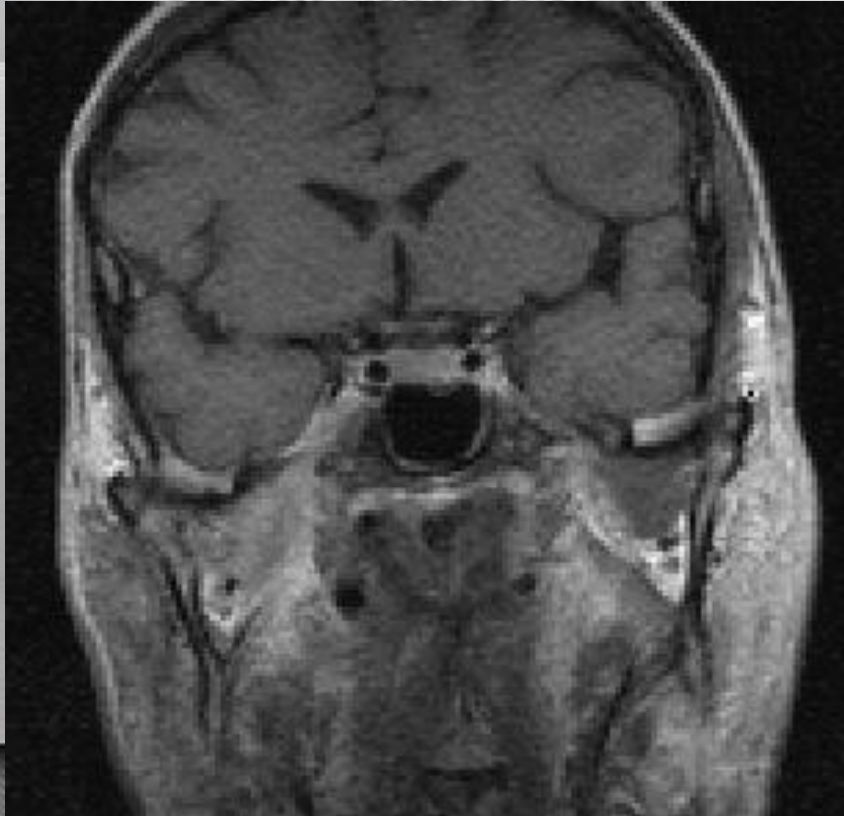
Masseter muscle hemangioma relatively common.



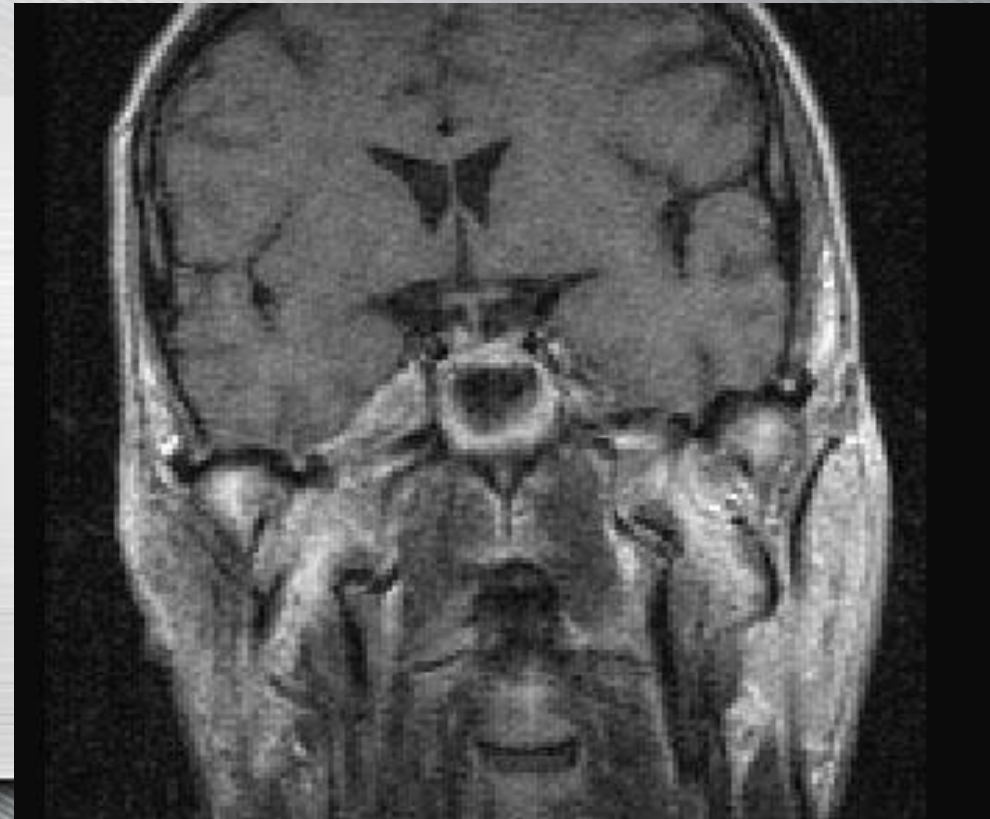Malignant fibro-histiocytoma in the masticator space with perineural spread



Malignant fibro-histiocytoma in the masticator space with perineural spread

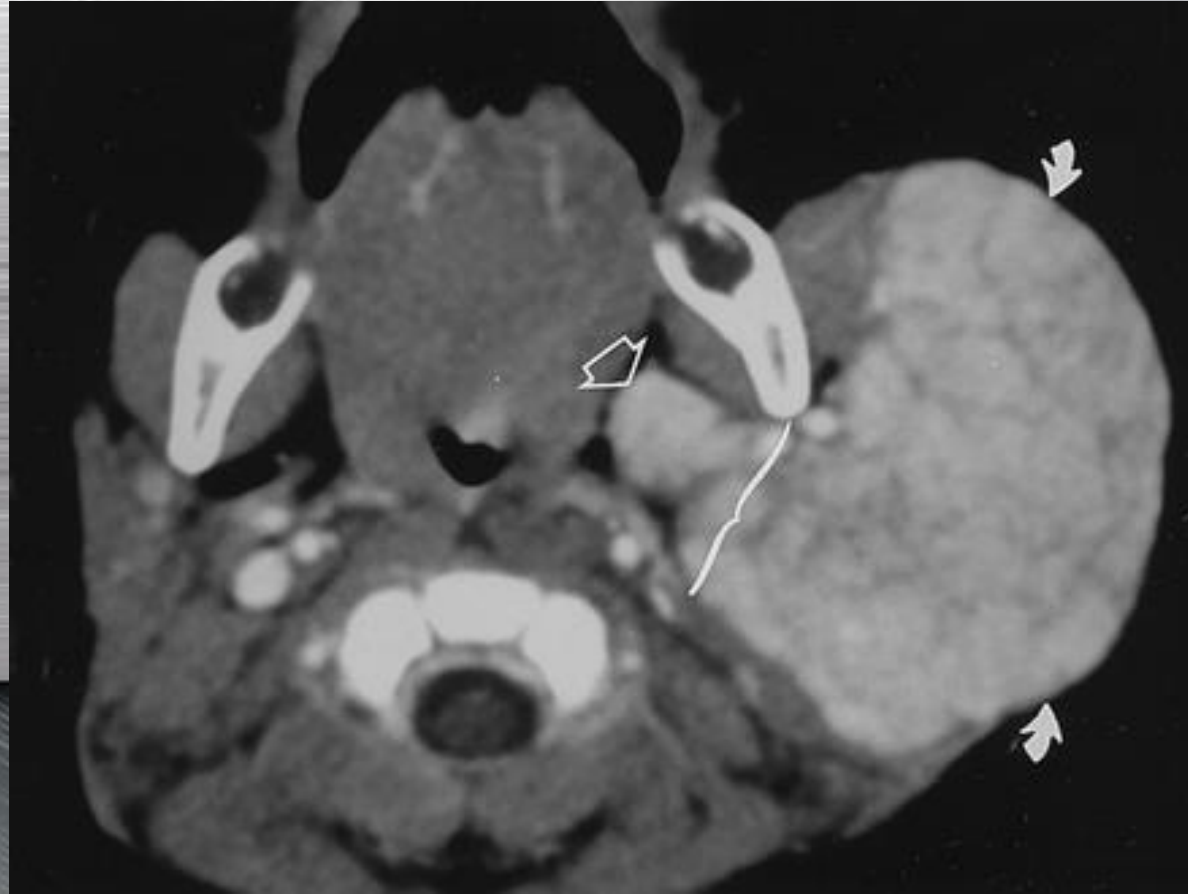

Cavernous sinus and Gasser ganglion are widened and enhance. The Meckel's cave is obstructed on the right



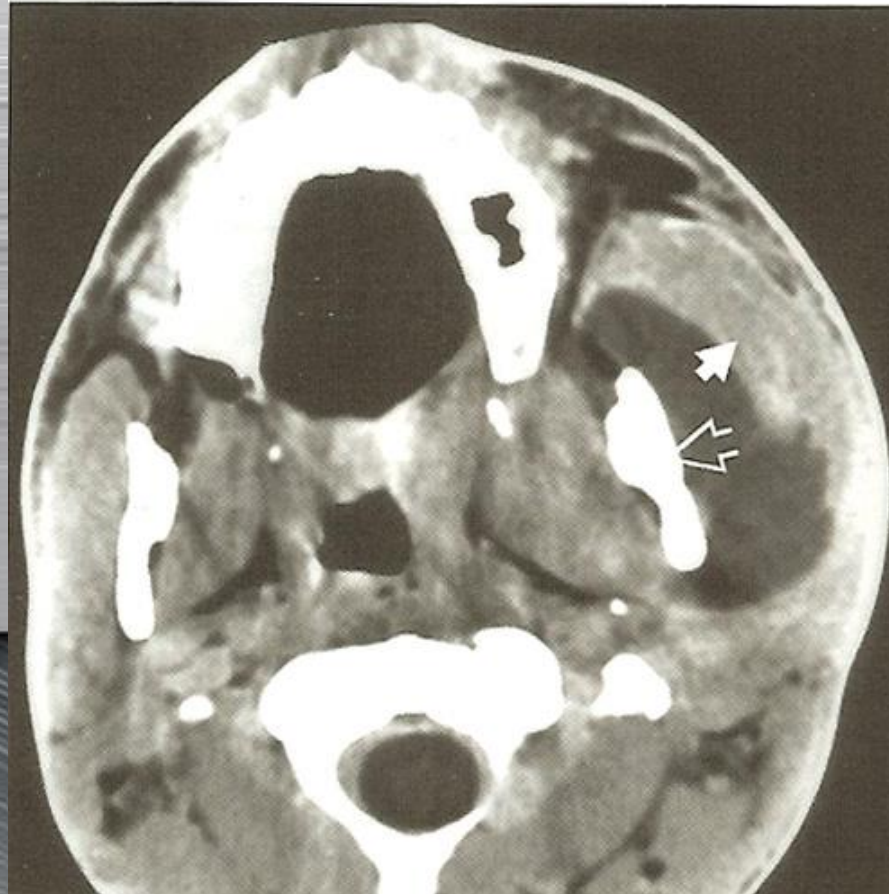widening of the foramen ovale and tumour all around the way of the inferior maxillary nerve

Hemangioma

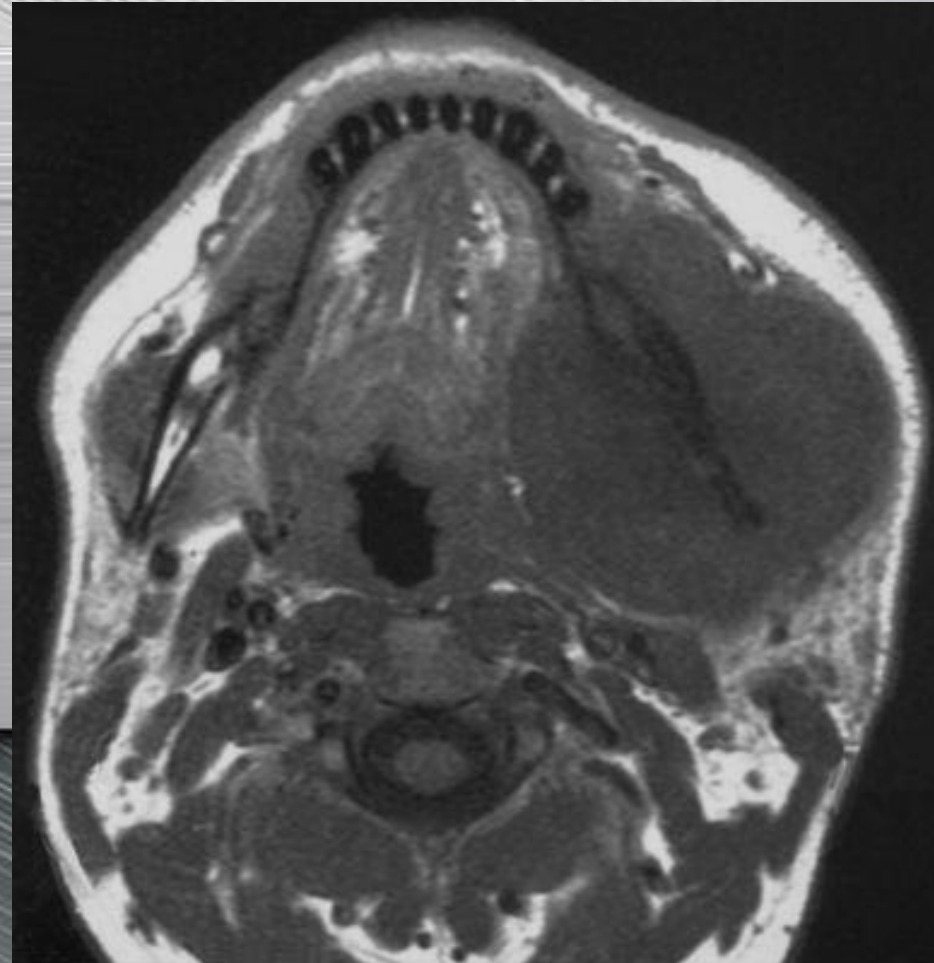


Masticator abscess

Masticator Space Abscess



Osteosarcoma



Lymphoma and metastasis can look the same

Schwannoma of the infratemporal fossa

