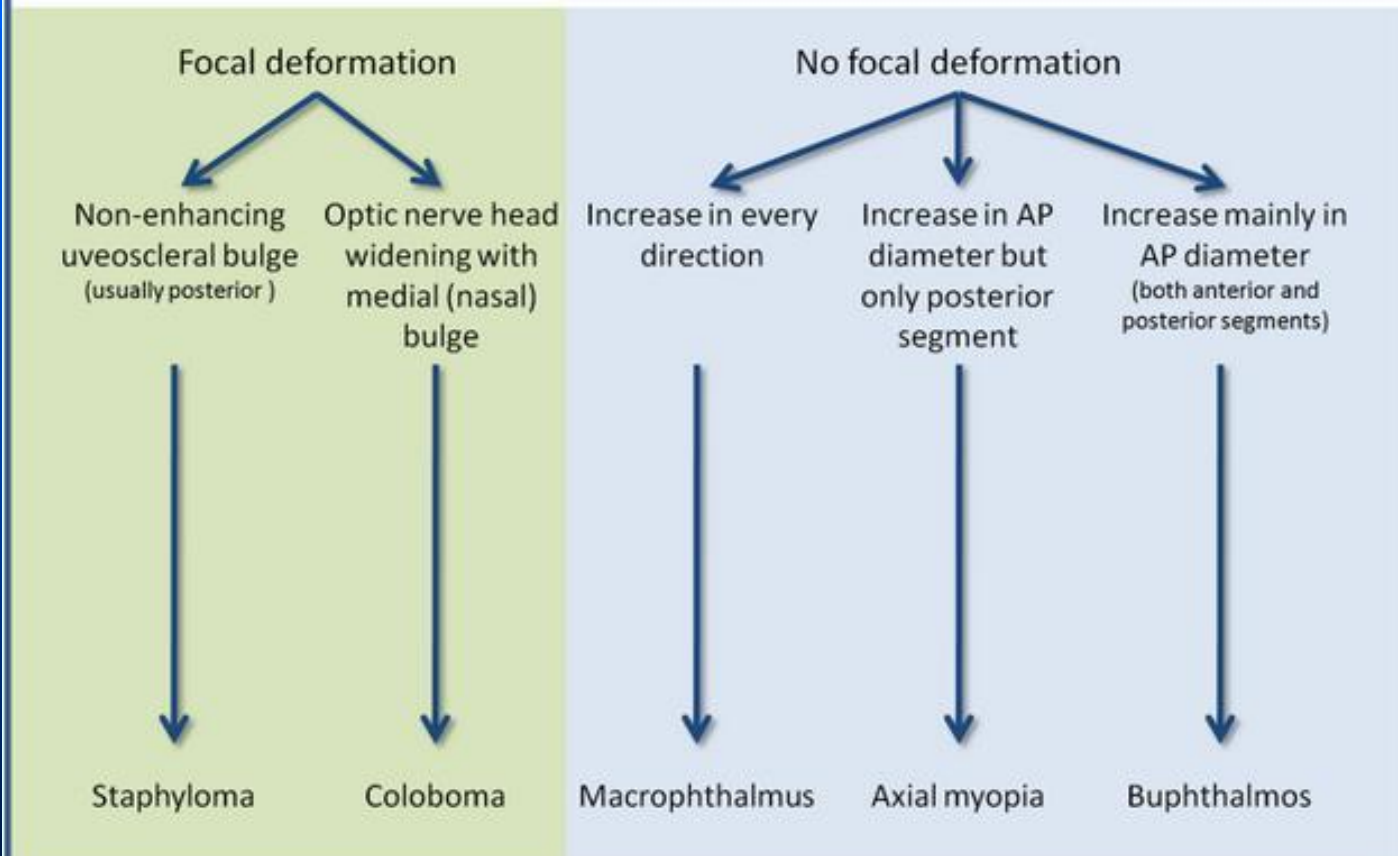


# Macrophthalmos

- Elongated globe in anteroposterior (AP) dimension may be secondary to myopia, staphyloma, or coloboma
- Diffuse enlargement of globe in AP and transverse dimension = buphthalmos ("ox eye" or "cow eye")
  - Buphthalmos may be present in congenital glaucoma, neurofibromatosis type 1 (NF1), Sturge-Weber, acquired glaucoma

## Increased size of the globe (eye) – differential diagnosis



Adapted from D Osborne, GN Foulks "Computed Tomographic Analysis of Deformity and Dimensional Changes in the Eyeball" Radiographics 1985; 153:699-674

# Buphthalmos

- Descriptive term which simply means an enlarged eyeball or ocular globe due to increased intraocular pressure (glaucoma), without deformation or and intrinsic mass lesion