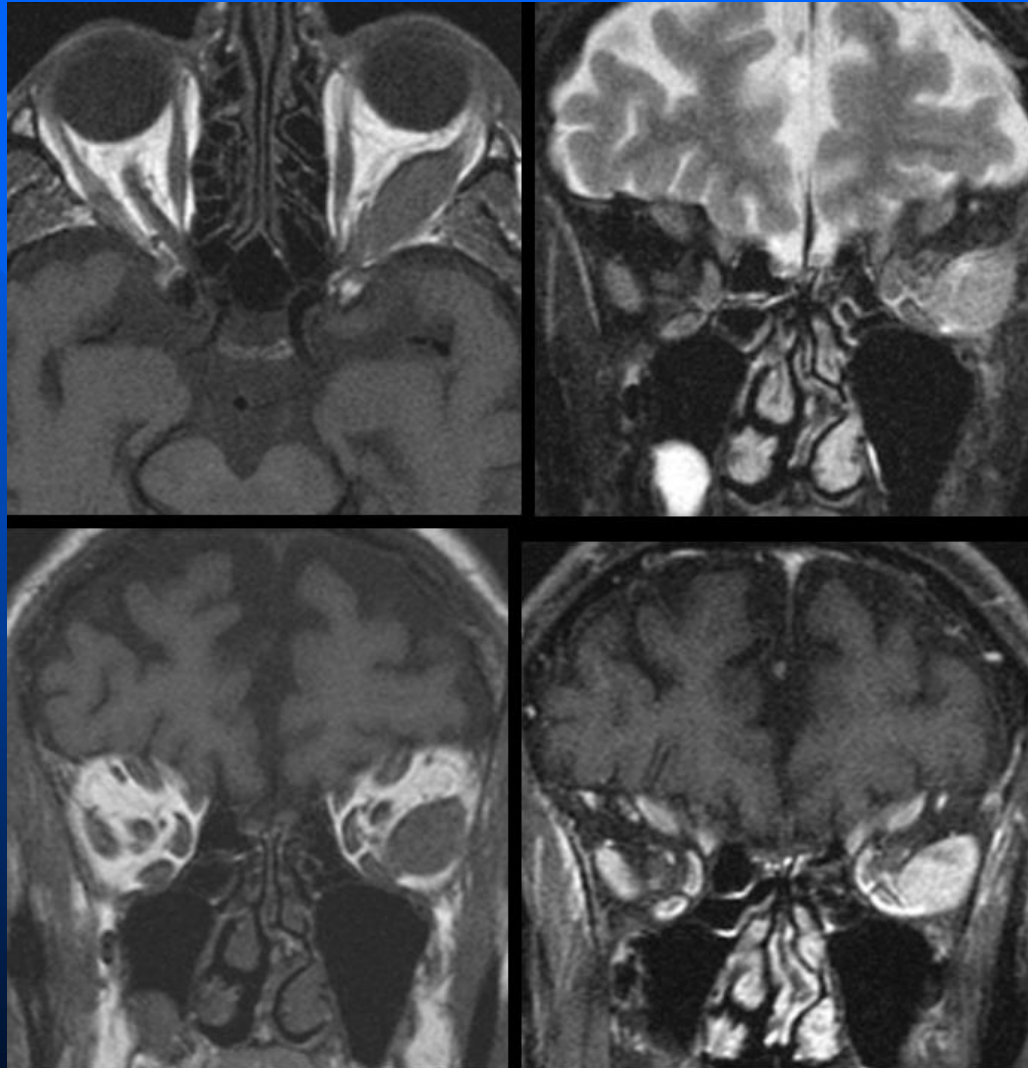
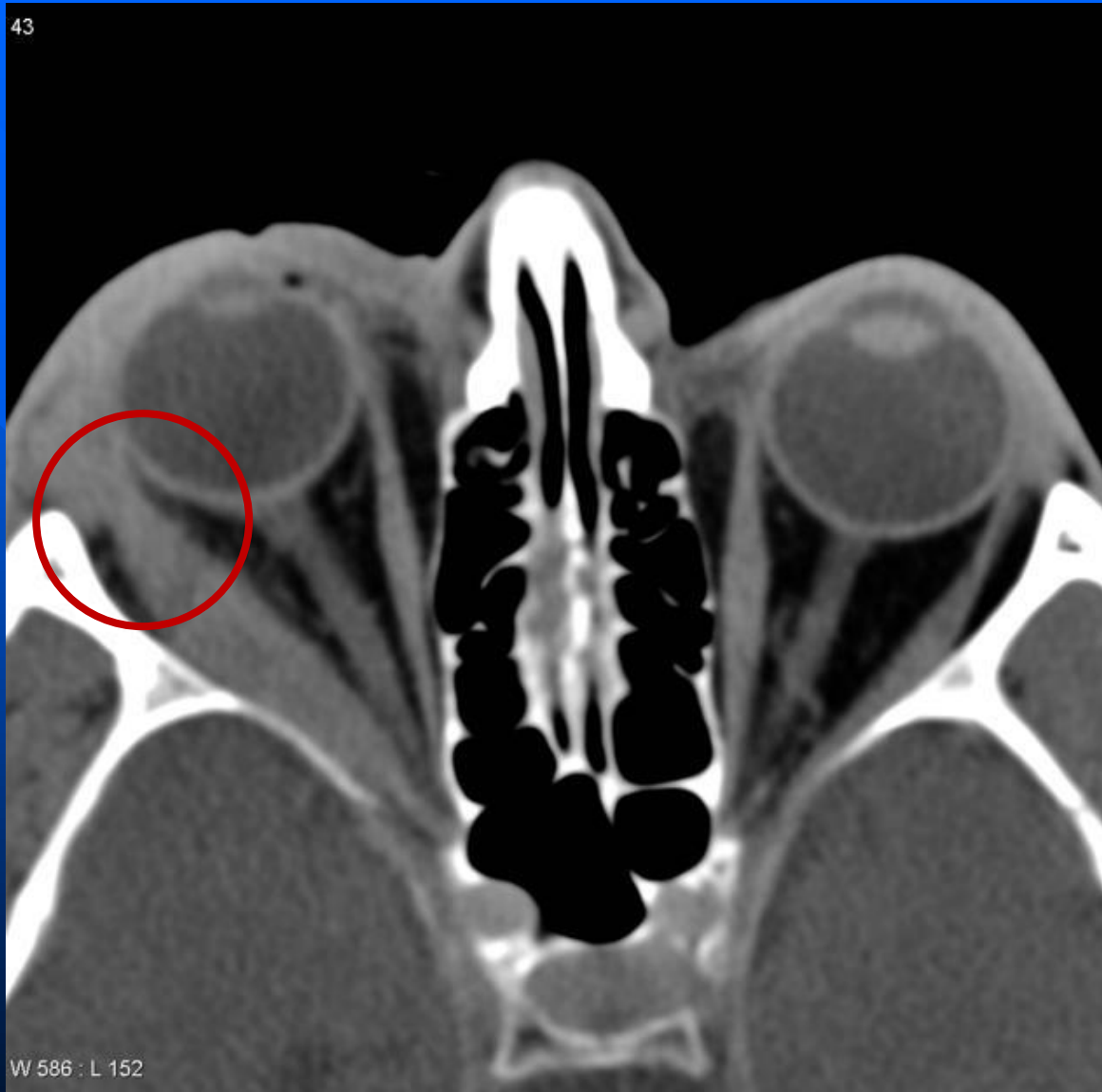


Pseudo tumor



43



W 586 : L 152

Imaging

- Enlargement of the muscle belly of one (or more) extraocular muscles with involvement of their tendinous insertions.
- Involvement of the tendinous insertion distinguishes it from thyroid associated orbitopathy (TAO) in which the insertion point is spared.