

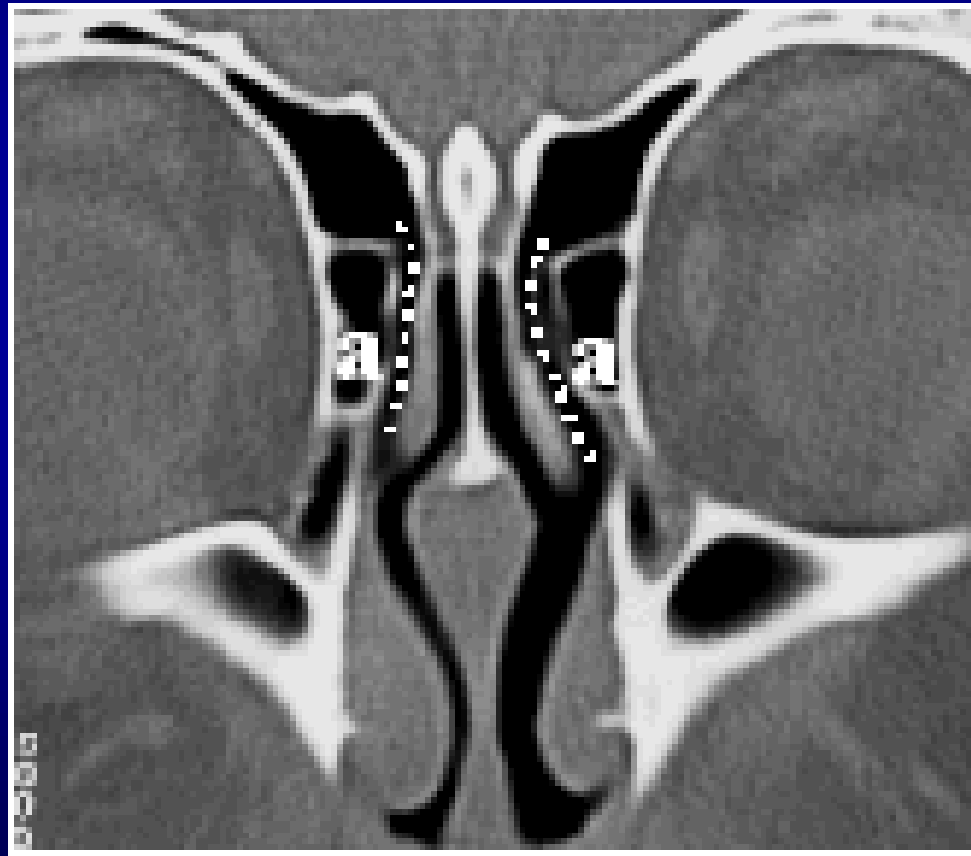
# Agger nasi cells

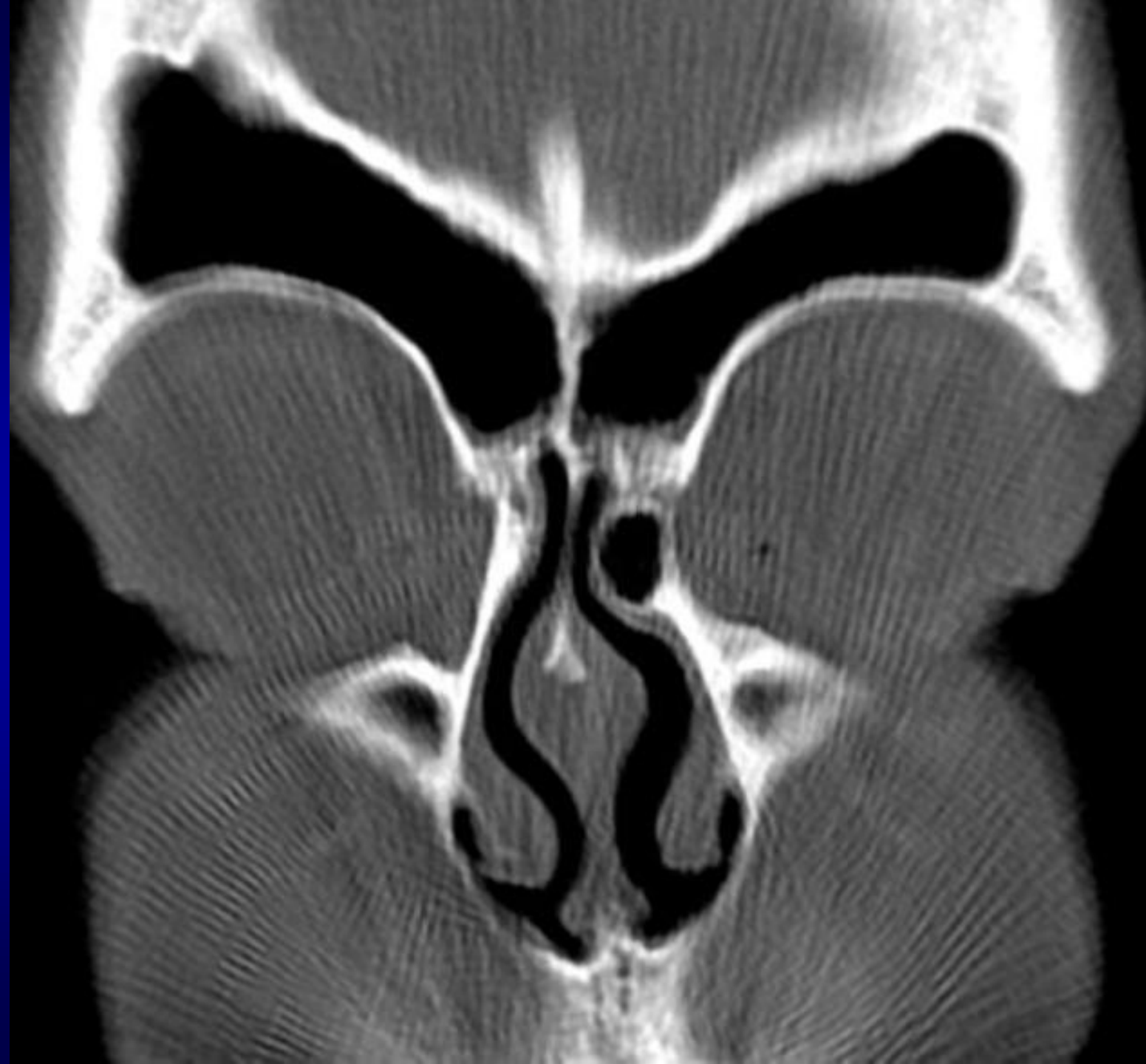- Most anterior ethmoidal air cells lying anterolateral and inferior to the frontoethmoidal recess and anterior and above the attachment of the middle turbinate.
- They are located within the lacrima bone and therefore have as lateral relations the orbit, the lacrima sac and the nasolacrima duct.

# Clinically significant

- They are identified in 90% of patients, and should not be confused with Haller cells (located along the medial floor of the orbit) or supraorbital air cells (located in the orbital roof).
- They may contribute to chronic frontal sinusitis <sup>3</sup>.

# Agger nasi cells





# Anatomy

