

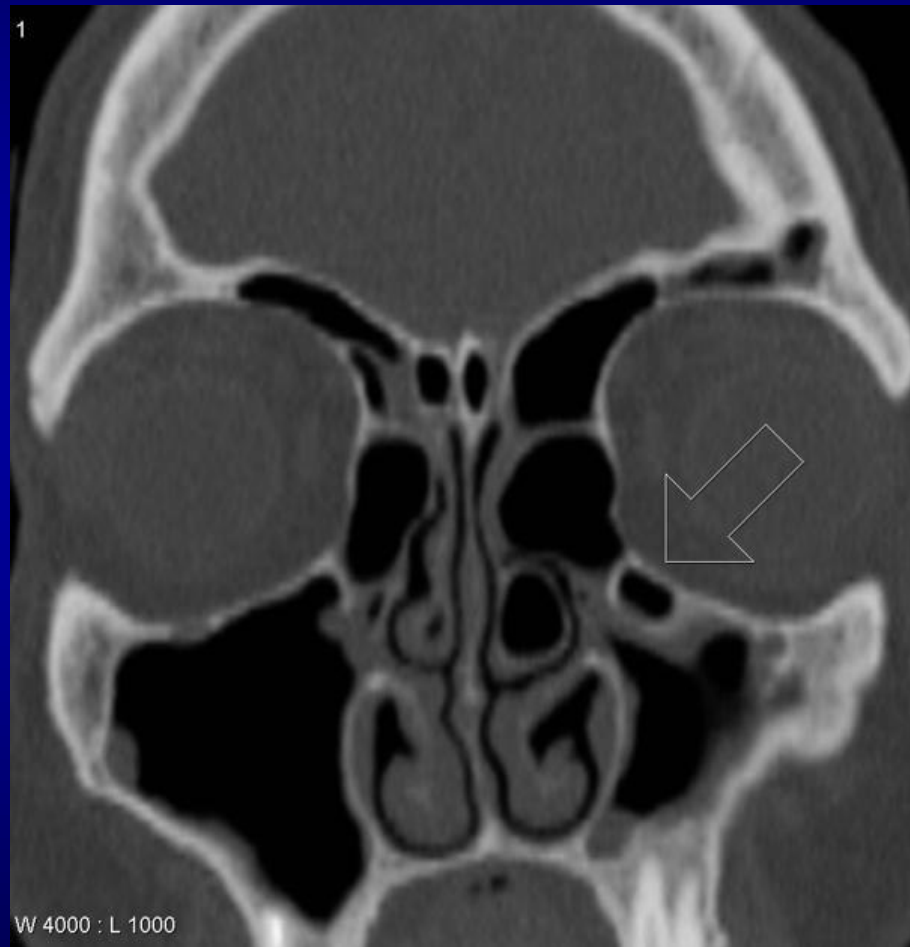
Haller Cells

- **Infraorbital ethmoidal air cells or maxilloethmoidal cells.**
- They are extramural ethmoidal air cells that extend into the inferomedial orbital floor and are present in ~20% (range 2-45%) of patients, depending on their exact definition.
- In most instances they are asymptomatic and (although some controversy exists ⁴⁻⁵)
- They are generally not thought to be associated with increased rates of sinusitis .

Clinically significant

- They become infected, with the potential for extension into the orbit
- May narrow the ipsilateral ostiomeatal complex (OMC) if large, thereby predisposing the ipsilateral maxillary antrum to obstruction ⁴
- May lead to inadvertent entry into the orbit if unrecognized at endoscopic surgery ⁴

Haller Cells



Anatomy

