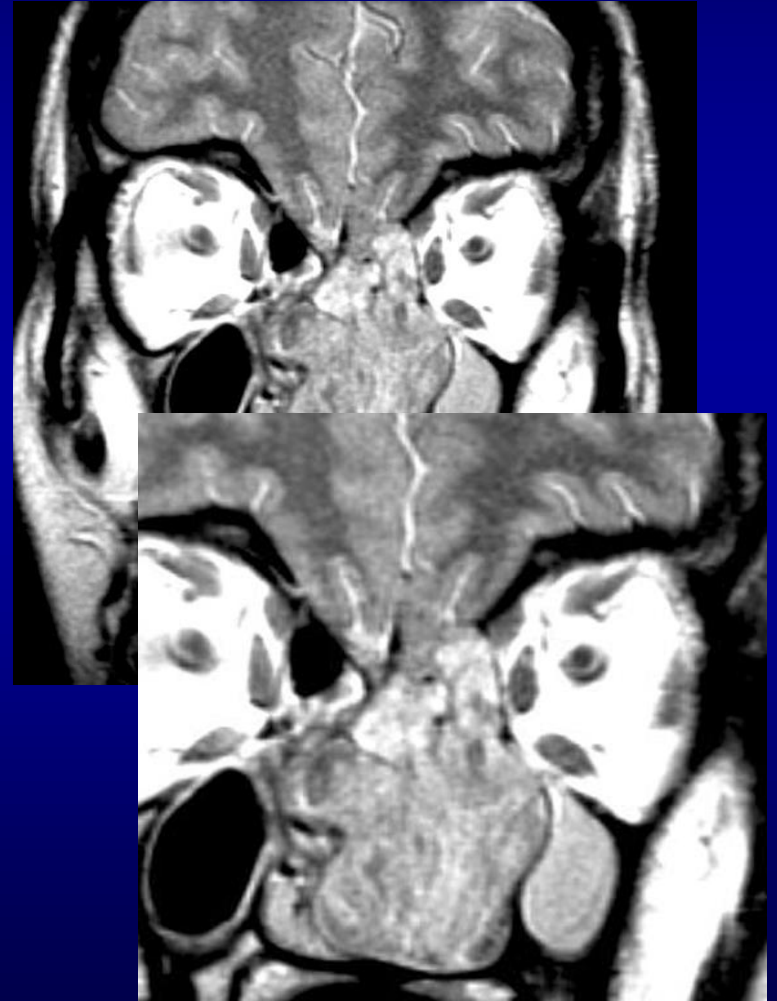


Malignancies of Glandular Origin

- 10% of all sinus tumors
- Bone destruction
- May be ↑ SI on T2
 - Adenocarcinoma
 - Adenoid cystic ca
 - Mucoepidermoid ca



Adenoid cystic ca

- Sinus mass with erosion of hard palate
- Perineural spread
 - Widened foramen or canal
 - Enlarged enhancing nerve
 - Obliteration of fat at skull base foramen

