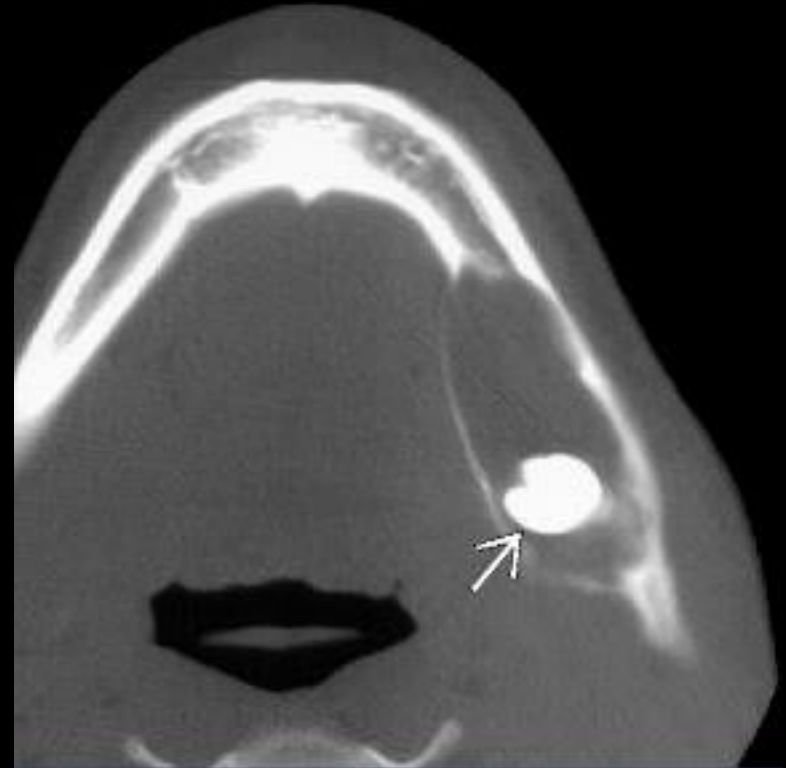
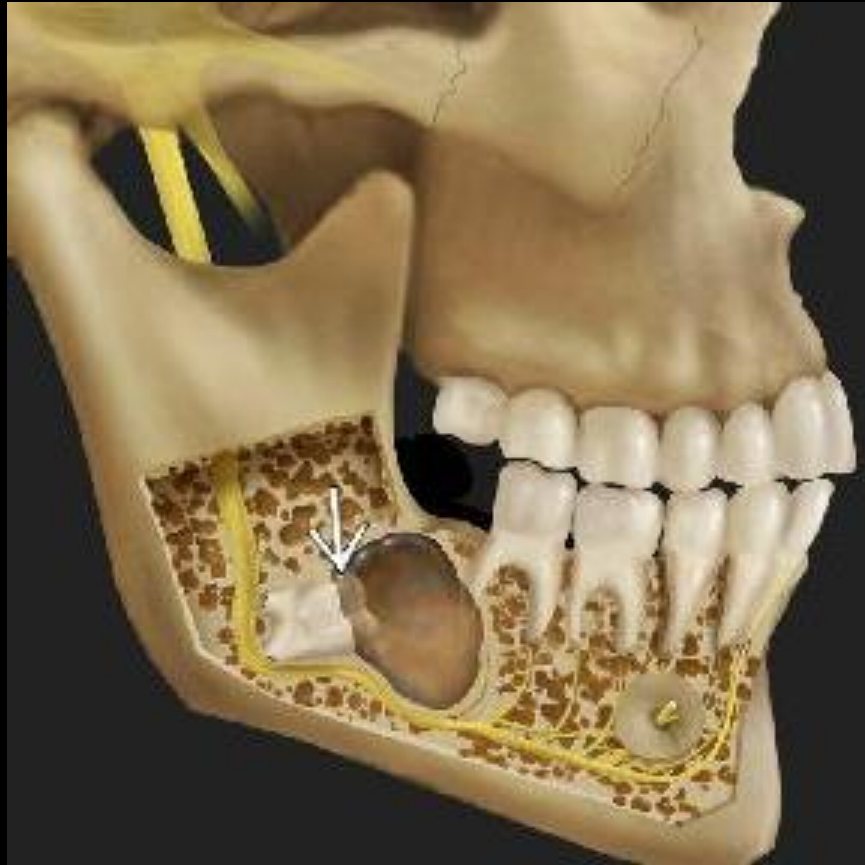

Dentigerous cyst



Dentigerous cyst

- Cyst arising from crown of unerupted tooth
- Best diagnostic clue: Radiolucent, well-circumscribed, expansile cyst surrounding CROWN of UNERUPTED, embedded or impacted tooth.
- Location: 75% located in mandible

DDX:

- **Radicular Cyst**
 - Small periapical cyst
- **Odontogenic keratocyst**
 - Multilocular cyst without associated unerupted tooth
- **Ameloblastoma**
 - Can be unilocular, with enhancing nodule within cyst
- **Metastasis**
 - Aggressive lesion with osseous destruction