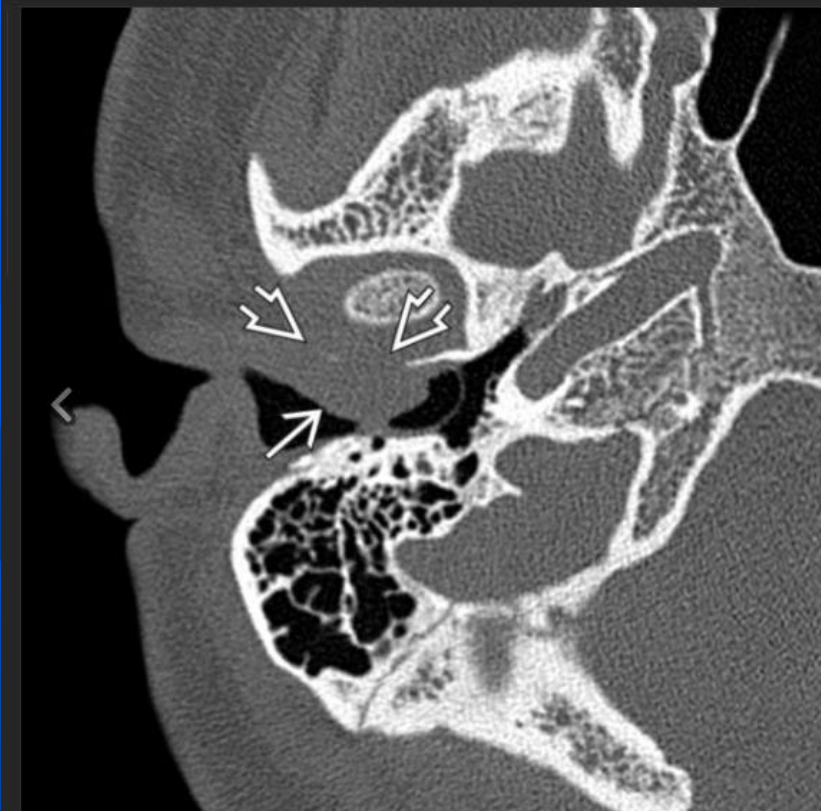


EAC Squamous Cell Carcinoma

- SCCa is most common malignancy of EAC.
- EAC debris, cholesteatoma, external otitis, and tumors may appear identical on imaging
- Bone destruction or soft tissue invasion indicates aggressive infection or malignancy.



[Download to Presentation](#)

Axial CT of temporal bone reveals an SCCa of the right EAC with prominent soft tissue mass → filling the right EAC. Osseous invasion anteriorly through the posterior wall of the right TMJ condylar fossa ⇨ is present.