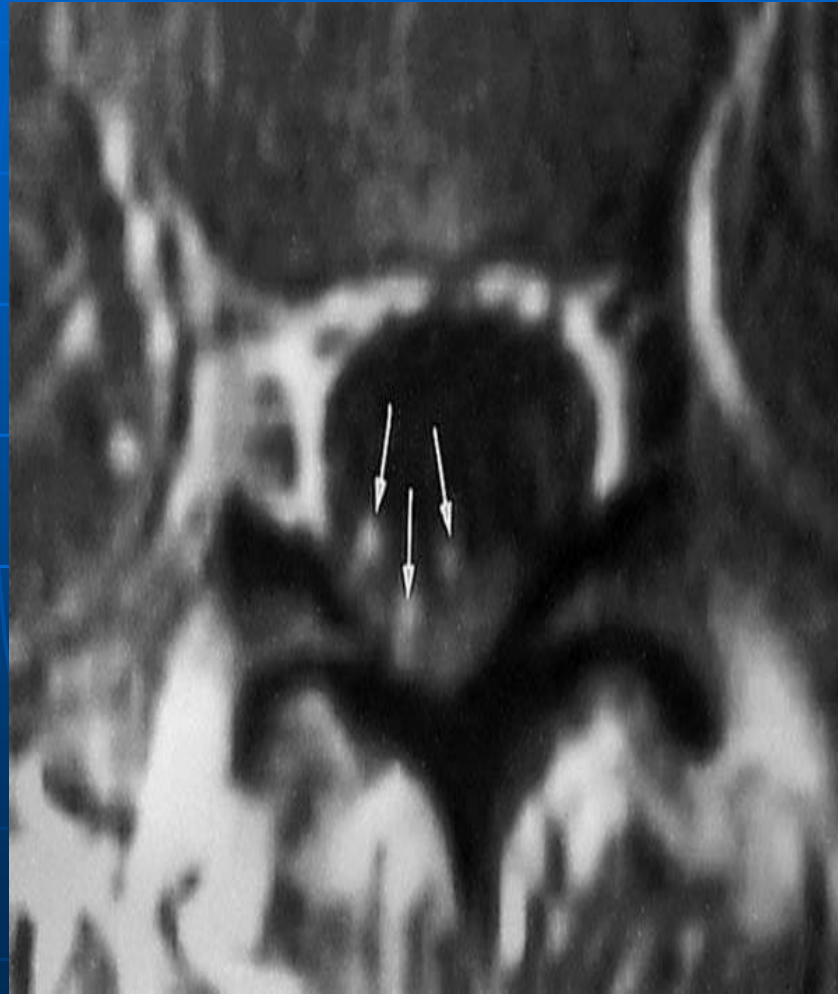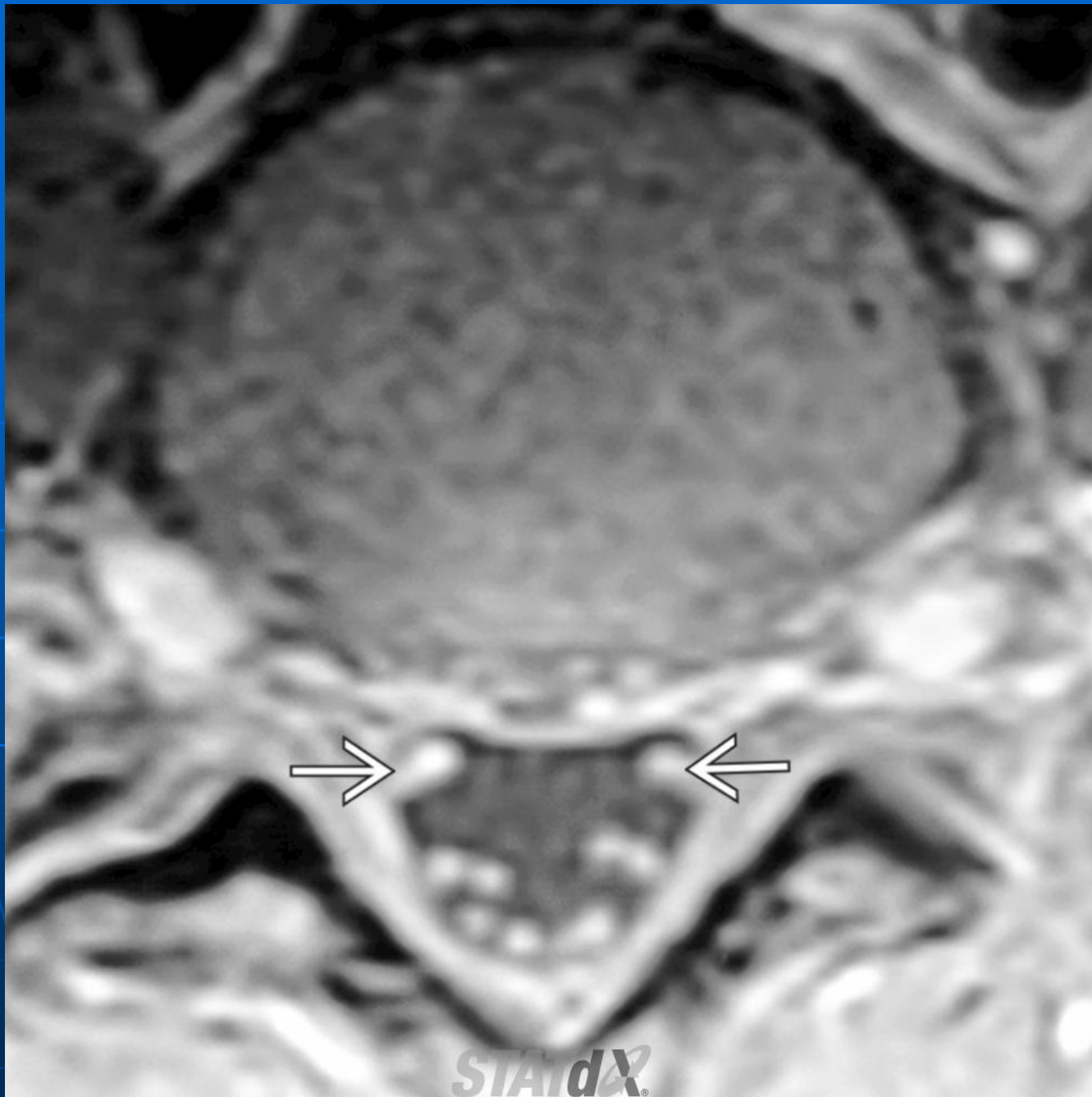


CMV with enhancing nerve roots





Axial T1WI C+ FS MR demonstrates diffuse cauda equina enhancement (white solid arrow) due to AIDS polyradiculopathy. This is the typical pattern for CMV radiculitis.