

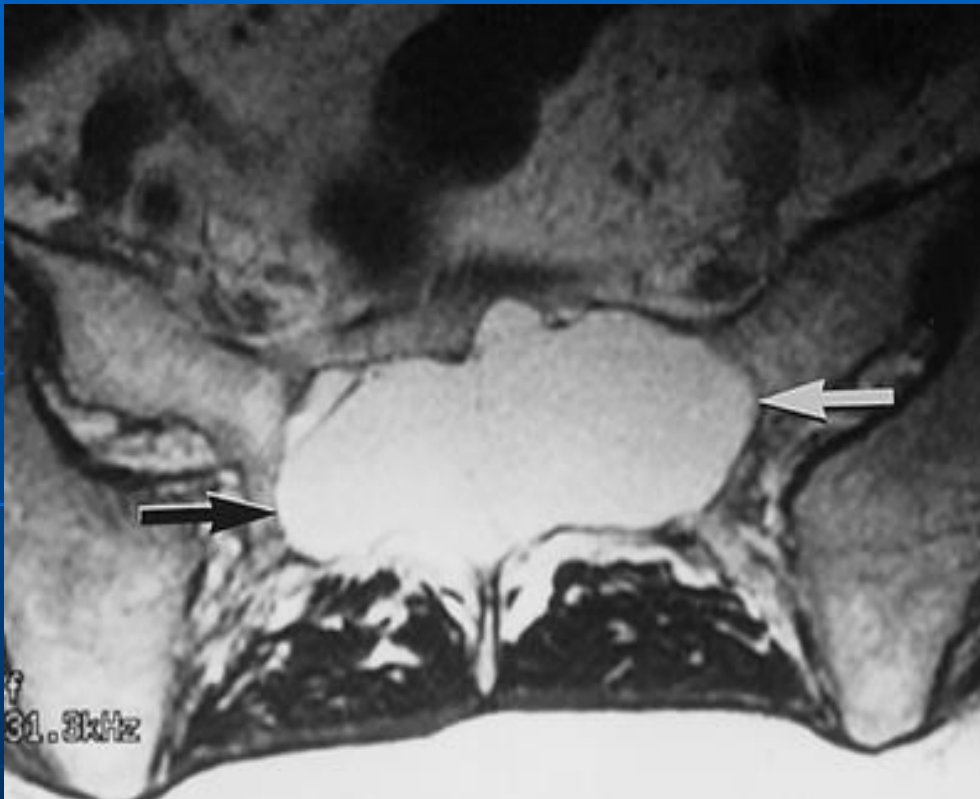# Dural ectasia

- Ballooning or widening of the dural sac which can result in posterior vertebral scalloping and is associated with herniation of nerve root sleeves.
- Present with low back pain or radicular pain in the buttocks or legs. Pain may be accompanied by leg weakness or urinary incontinence.
- Other associations include spondylolisthesis, scoliosis, vertebral erosions, and vertebral fractures.
- There is also an increased incidence of anterior sacral meningoceles which may present as an abdominal mass.

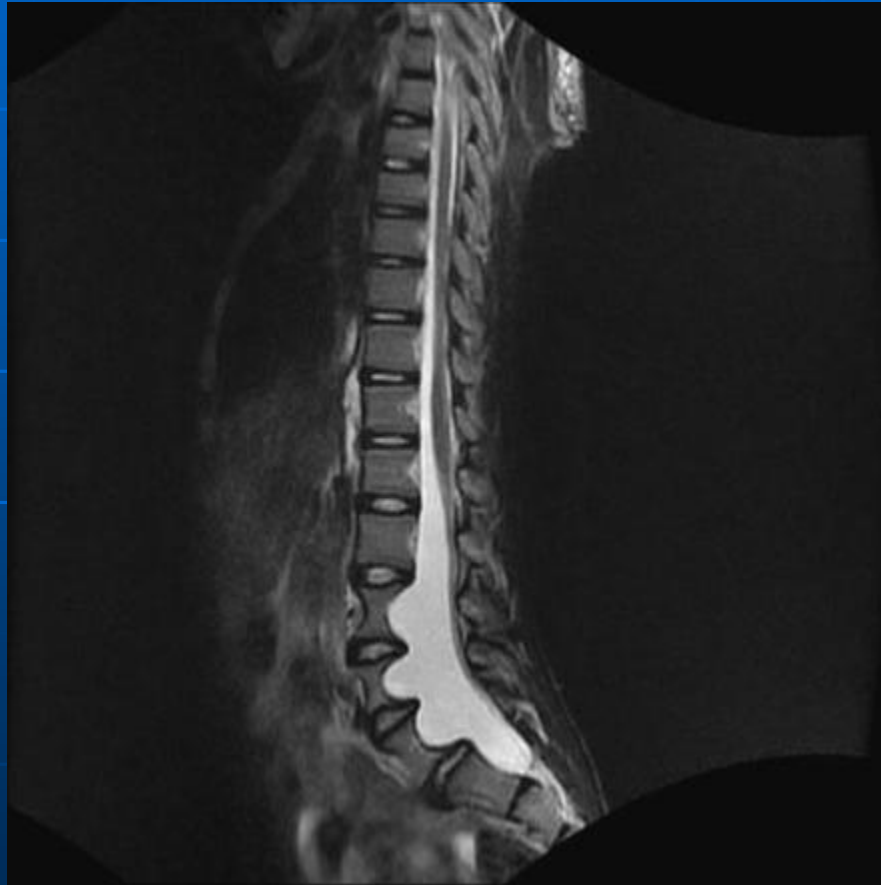
# Dural ectasia

## ***Causes***

1. Ankylosing spondylitis
2. Marfan's syndrome
3. Neurofibromatosis
4. Ehler-Dantos syndrome
5. Homocystinuria
6. OI
7. trauma
8. post surgery
9. tumors
10. scoliosis



# NF



# Ankylosing spondylitis

